



## PATIENT PRESENTING CLINICAL SIGNS

Levi Speagle limping left hind leg

## SPECIES

Canine

## RADIOGRAPHIC STUDY OF THE LEFT STIFLE

- Mediolateral and craniocaudal views of the left stifle including ventrodorsal hip extended radiograph of the pelvis totaling 3 images in JPEG format.

## BREED

Australian Shepherd

- Only jpg images were submitted. The transformation from DICOM to jpg only allows for limited manipulation of the image. For the best possible results, we suggest submitting DICOM images in the future. Please do not hesitate to contact us should you need any help with the submission process.

## SEX

MN

## RADIOGRAPHIC FINDINGS

The left stifle joint is radiographically unremarkable.

No evidence of articular enlargement, osteophyte formation, fracture, aggressive bone lesion or tibial translation is identified.

## AGE

5yr

Alignment of the bones is within normal limits.

There is no radiographic evidence of gastrocnemius muscular tendinopathy noted.

## INTERPRETED BY

Nele Eley (Ondreka),  
DVM Dr. med. vet.,  
DipECVDI

The included hips are unremarkable radiographically.

## RADIOGRAPHIC DIAGNOSIS

- Radiographically normal left stifle and coxofemoral joints

## HOSPITAL NAME

The Collegeway  
Animal Hospital

## INTERPRETATION OF FINDINGS & FURTHER RECOMMENDATIONS

No radiographic abnormalities identified to explain the reported left hind limb lameness. Early soft tissue, ligamentous, meniscus, neurologic or subtle orthopedic disease may not be visible radiographically.

## REFERRING VET

Dr. Ehab Hanna

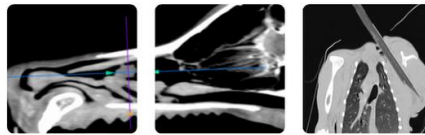
Correlation with orthopedic examination findings is recommended. Advanced or orthopedic referral may be considered if lameness persists or worsens.

## INVOICE

24845

## DATE

05/16/2026



## PATIENT

Levi Speagle

## SPECIES

Canine

## BREED

Australian Shepherd

## SEX

MN

## AGE

5yr

## INTERPRETED BY

Nele Eley (Ondreka),  
DVM Dr. med. vet.,  
DipECVDI

## HOSPITAL NAME

The Collegeway  
Animal Hospital

## REFERRING VET

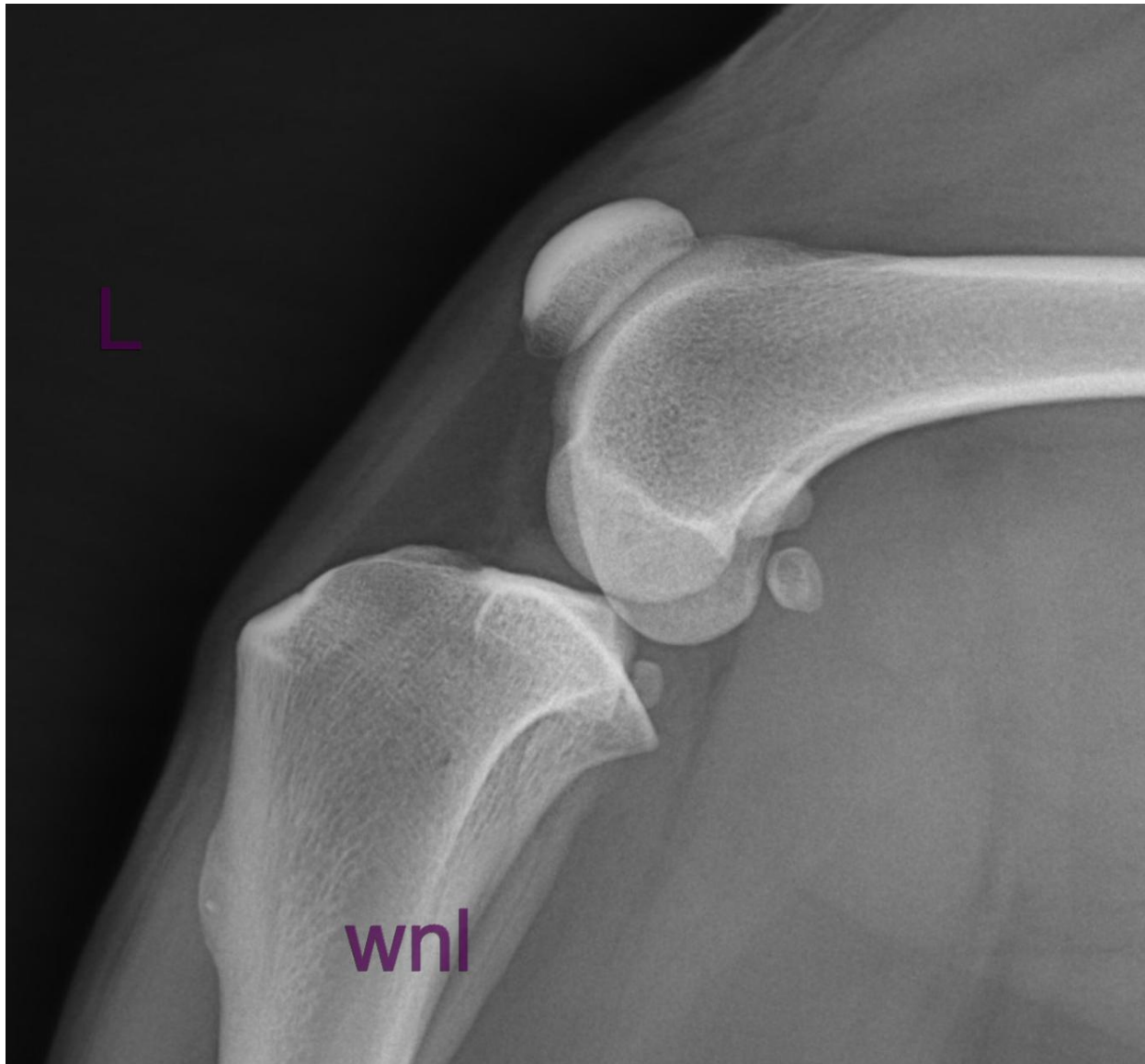Dr. Ehab Hanna

## INVOICE

24845

## DATE

05/16/2026





## PATIENT

Levi Speagle

The information and recommendations provided are based on the images presented by the referring veterinarian. No evaluation can be communicated regarding pathology that was not visible in the image/video clips provided.

## SPECIES

Canine

Thank you for this referral. If the clinical or image interpretation does not parallel your findings or if I can be of any further assistance please contact me.

## BREED

Australian Shepherd

**Nele Eley (Ondreka)**, DVM, Dr. med. vet., DipECVDI  
European Specialist in Veterinary Diagnostic Imaging, Cert. Radiology,  
Senior lecturer University of Giessen/Germany, Veterinary Faculty, Department of Radiology.  
[info@sonopath.com](mailto:info@sonopath.com)

## SEX

MN

## AGE

5yr

## INTERPRETED BY

Nele Eley (Ondreka),  
DVM Dr. med. vet.,  
DipECVDI

## HOSPITAL NAME

The Collegeway  
Animal Hospital

## REFERRING VET

Dr. Ehab Hanna

## INVOICE

24845

## DATE

05/16/2026