



## PATIENT

Houdie Bland

## SPECIES

Canine

## BREED

French Bulldog

## SEX

Neutered Male

## AGE

11Y

## WEIGHT

30

## INTERPRETED BY

Nele Eley (Ondreka),  
DVM Dr. med. vet.,  
DipECVDI

## IMAGING PERFORMED BY

EHAH

## HOSPITAL NAME

East Hill Animal  
Hospital

## REFERRING VET

Laura Hall

## INVOICE

75012

## DATE

5-14-26

## PRESENTING CLINICAL SIGNS

Patient was seen yesterday for lethargy and appeared dazed on a walk, requiring owner to carry him home. Has history of similar episode that resulted in vomiting and seizures. Currently barely walking, hunched posture, tremors, not eating or drinking. Will not lift right leg to urinate, only lifting left leg. Could barely stand this morning. Condition has worsened since yesterday.

## COMPUTED TOMOGRAPHIC STUDY OF THE HEAD, THORAX, ABDOMEN, CERVICAL, THORACIC, & LUMBAR SPINE

Plain and post IV contrast studies are available for review.

## COMPUTED TOMOGRAPHIC FINDINGS

### Head

No overt intracranial abnormality is identified on the CT examination.

There is no evidence of intracranial hemorrhage. A space occupying mass effect is not seen. Significant hydrocephalous is not present.

CT sensitivity for certain intracranial parenchymal disease however remains limited.

A mild amount of soft tissue attenuating material fills the left external ear canal and tympanic bulla consistent with left sided otitis externa and otitis media.

Multiple teeth are absent. Full thickness alveolar bone defect is present at the site of the previously extracted left maxillary canine tooth 204 covered by soft tissue. No evidence of active oronasal fistula or active rhinitis is identified.

### Spine

At C3/4, there is a partially mineralized intervertebral disc extrusion with associated narrowing of the intervertebral disc space. Moderate to severe spinal cord compression is present with approximately 40% of the vertebral canal diameter occupied by extradural disc material.

Mild chronic intervertebral disc protrusion is present at C7/T1 without marked spinal cord compression.

Hemivertebrae are present at T3, T5, T6, and T7 with associated mild focal kyphosis and mild vertebral canal stenosis.

Chronic mild intervertebral disc protrusions are present at L1/2, L2/3, and L3/4 with mild to moderate associated spondylosis deformans.

Mild lumbosacral stenosis is identified.

Multiple intervertebral discs demonstrate mineralization.

### Thorax

The bony and surrounding soft tissue structures are within normal limits.



## PATIENT

Houdie Bland

## SPECIES

Canine

## BREED

French Bulldog

## SEX

Neutered Male

## AGE

11Y

## WEIGHT

30

## INTERPRETED BY

Nele Eley (Ondreka),  
DVM Dr. med. vet.,  
DipECVDI

## IMAGING PERFORMED BY

EHAH

## HOSPITAL NAME

East Hill Animal  
Hospital

## REFERRING VET

Laura Hall

## INVOICE

75012

## DATE

5-14-26

The sternal, cranial mediastinal and tracheobronchial lymph nodes are small elongated with a normal short-to-long-axis-ratio is  $< 0.5$ , the attenuation and contrast enhancement pattern are uniform and considered within normal limits.

The cardiovascular structures including the pulmonary vasculature are within normal limits.

The bronchial tree presents with regular branching and tapers uniformly towards the periphery as expected, the bronchial walls are thin and smooth. The bronchus-to-artery ratio is within normal limits.

Mild age related pulmonary parenchymal changes are present with no evidence of focal pulmonary mass, pneumonia, pleural effusion, or pneumothorax.

Small incidental gas pockets are seen within the esophageal lumen; there is no evidence of abnormal dilation.

### Abdomen

The serosal fat presents normal attenuation behavior. There is no evidence of peritoneal effusion or peritonitis.

Both kidneys present within normal limits for size, shape and organ architecture. After contrast administration, a bilaterally symmetric and uniform nephro- and pyelogram is noted.

The adrenal glands are within normal limits for size, shape and organ architecture.

Both liver and spleen present with normal shape, even surface, uniformly attenuating parenchyma and homogeneous contrast enhancement, unremarkable.

The pancreas is evenly contoured; the pancreatic parenchyma is homogeneous and presents uniform contrast enhancement.

The position, delineation, wall and content of the gastrointestinal tract are considered within normal limits throughout.

### COMPUTED TOMOGRAPHIC DIAGNOSIS

- Partially mineralized intervertebral disc extrusion at C3/4 causing moderate to severe spinal cord compression.
- Mild chronic multilevel degenerative intervertebral disc disease including C7/T1 and L1-L4 regions.
- Multiple congenital thoracic hemivertebrae with mild focal kyphosis and mild vertebral canal stenosis.
- Chronic left sided otitis externa and otitis media.
- No overt CT abnormality of the brain identified.
- Multiple chronic dental post-extraction changes including full thickness defect at 204 without evidence of active rhinitis.
- No significant thoracoabdominal abnormality identified.

### INTERPRETATION OF FINDINGS & FURTHER RECOMMENDATIONS

The most clinically significant imaging abnormality is the C3/4 disc extrusion with associated moderate to severe spinal cord compression. This may reflect an acute or chronic process which could possibly contribute to weakness, ataxia, cervical discomfort, and reduced mobility. The absence of overt



## PATIENT

Houdie Bland

## SPECIES

Canine

## BREED

French Bulldog

## SEX

Neutered Male

## AGE

11Y

## WEIGHT

30

## INTERPRETED BY

Nele Eley (Ondreka),  
DVM Dr. med. vet.,  
DipECVDI

## IMAGING PERFORMED BY

EHAH

## HOSPITAL NAME

East Hill Animal  
Hospital

## REFERRING VET

Laura Hall

## INVOICE

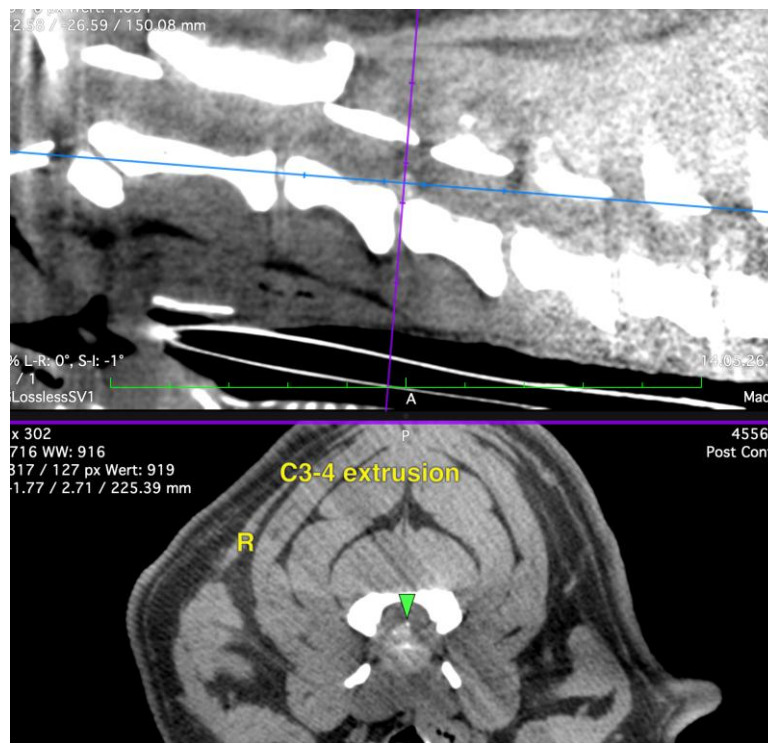
75012

## DATE

5-14-26

intracranial abnormality on CT is reassuring, however, CT has limited sensitivity for intracranial disease including inflammatory, intraaxial, infiltrative, ischemic encephalitis, seizure associated change, and small parenchymal lesions. MRI of the brain may still be warranted if clinical concern for intracranial disease persists.

Consider otoscopic workup.



The information and recommendations provided are based on the images presented by the referring veterinarian. No evaluation can be communicated regarding pathology that was not visible in the image/video clips provided.

Thank you for this referral. If the clinical or image interpretation does not parallel your findings or if I can be of any further assistance please contact me.

**Nele Eley (Ondreka)**, DVM, Dr. med. vet., DipECVDI  
European Specialist in Veterinary Diagnostic Imaging, Cert. Radiology,  
Senior lecturer University of Giessen/Germany, Veterinary Faculty, Department of Radiology.  
[info@sonopath.com](mailto:info@sonopath.com)