



**PATIENT**

Jessie Schmidt

**PRESENTING CLINICAL SIGNS**

P has had toe-touching or non-weight bearing lameness for the last 24 hours P went to reach for a toy and landed poorly on her left hindlimb P expressed immediate pain on occurrence, but has not appeared painful since then

**SPECIES**

Canine

Abnormal PE/Chem/CBC/UA Results: Non-weight bearing lameness of the left hindlimb, P appears to want to ambulate the limb, but no flexion is noted of the stifle. Moderate inflammation is noted of the hindlimb (improves distally). No appreciable pain on extension of the limb, with some pain response on palpation of the stifle.

**BREED**

French Bulldog

**RADIOGRAPHIC STUDY OF THE STIFLES**

Mediolateral and craniocaudal views of both stifles totaling 3 images available for review.

**RADIOGRAPHIC FINDINGS**

**SEX**

Female

Moderate cranial and proximal displacement of the left tibial tuberosity is noted. There is distal soft tissue swelling of the patella tendon. No evidence of concurrent epiphyseal displacement of the proximal tibia is seen. The femoral tibial joint appears to be in situ. The patella is in situ. The distal femoral growth plate presents within normal limits. No evidence of muscle atrophy is noted.

**AGE**

5 Months

The right stifle presents within normal limits.

**INTERPRETED BY**

Nele Eley, DVM  
Dr. med. Vet. DipECVDI

**RADIOGRAPHIC DIAGNOSIS**

- Complete traumatic avulsion of the left tibial tuberosity with traumatic tendinopathy of the left patella tendon.

**INTERPRETATION OF THE FINDINGS & FURTHER RECOMMENDATIONS**

The radiographic findings are compatible with Salter Harris type 1 or 2 apophyseal lysis of the tibial tuberosity in the left hind limb. The findings of the patella tendon suggest concurrent traumatic patella tendinopathy. No evidence of patella alta is seen and the injury appears to be isolated to the apophyseal growth plate. The proximal and distal epiphysis of the tibia and femur present within normal limits, respectively.

**HOSPITAL NAME**

Boca Park Animal  
Hospital

**REFERRING VET**

Tifanie Silver

**INVOICE**

52143

**DATE**

5-14-22



**PATIENT**

Jessie Schmidt

**SPECIES**

Canine

**BREED**

French Bulldog

**SEX**

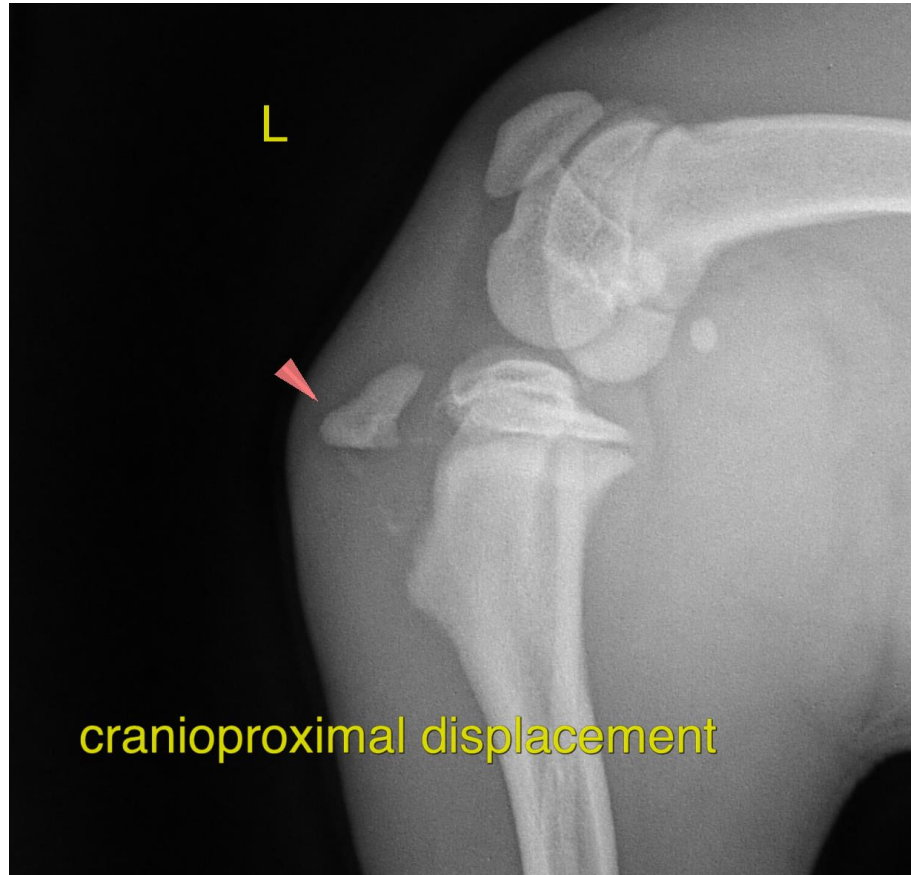
Female

**AGE**

5 Months

**INTERPRETED BY**

Nele Eley, DVM  
Dr. med. Vet. DipECVDI



**HOSPITAL NAME**

Boca Park Animal  
Hospital

**REFERRING VET**

Tifanie Silver

**INVOICE**

52143

**DATE**

5-14-22

The information and recommendations provided are based on the images presented by the referring veterinarian/sonographer. No evaluation can be communicated regarding pathology that was not visible in the image/video clips provided.

Thank you for this referral. If the clinical or image interpretation does not parallel your findings or if I can be of any further assistance please contact me.

**Nele Eley**, DVM, Dr. med. vet., DipECVDI  
European Specialist in Veterinary Diagnostic Imaging, Cert. Radiology,  
Senior lecturer University of Giessen, Germany, Veterinary Faculty, Department of Radiology  
Nele.Eley@sonopath.com