



PATIENT

Casper Rependa

PRESENTING CLINICAL SIGNS

Suspect bilateral elbow dysplasia (L>R) vs overuse

SPECIES

Canine

COMPUTED TOMOGRAPHIC STUDY OF THE ELBOWS

Plain study in soft tissue and bone windows available for review.

BREED

Golden Retriever

COMPUTED TOMOGRAPHIC FINDINGS

Both elbow joints present within normal limits. The joint spaces are congruent. There is no evidence of osteochondritis or medial coronoid pathology. The medial coronoid contour is well delineated. The attenuation presents no deviation from the expected anatomy other than mild sclerosis. However, no fragmentation or fissuring is seen. The periarticular margins are smooth and intact.

SEX

M

Mild patchy increase in medullary cavity opacity is seen in the humerus in both front limbs.

AGE

8 Months

COMPUTED TOMOGRAPHIC DIAGNOSIS

- Normal age related findings of the elbows with no evidence of medial coronoid pathology or osteochondritis.
- Suspect panosteitis eosinophilica.

INTERPRETED BY

Nele Eley, DVM
Dr. med. Vet. DipECVDI

INTERPRETATION OF THE FINDINGS & FURTHER RECOMMENDATIONS

The CT study reveals no evidence of medial coronoid pathology, osteochondritis, or other form of elbow dysplasia. At this time, no fragmentation or fissuring is seen in the medial coronoid processes and there are no signs of arthritis or osteoarthritis.

HOSPITAL NAME

Animal Health
Partners

Consider the potential of panosteitis eosinophilica which can cause intermittent and shifting lameness and is a juvenile and inflammatory disorder that ceases with reaching skeletal maturity. Systemic NSAID administration, rest, and restriction of the daily caloric intake can help alleviate the clinical signs in the meantime.

REFERRING VET

Dr. Jeffery Biskup

INVOICE

52144

DATE

5-14-22



PATIENT

Casper Rependa

SPECIES

Canine

BREED

Golden Retriever

SEX

M

AGE

8 Months

INTERPRETED BY

Nele Eley, DVM
Dr. med. Vet. DipECVDI

HOSPITAL NAME

Animal Health
Partners

REFERRING VET

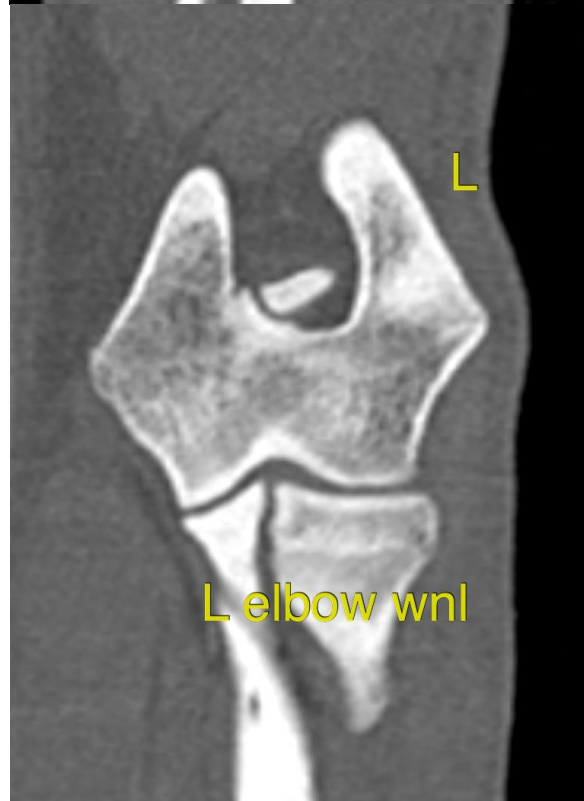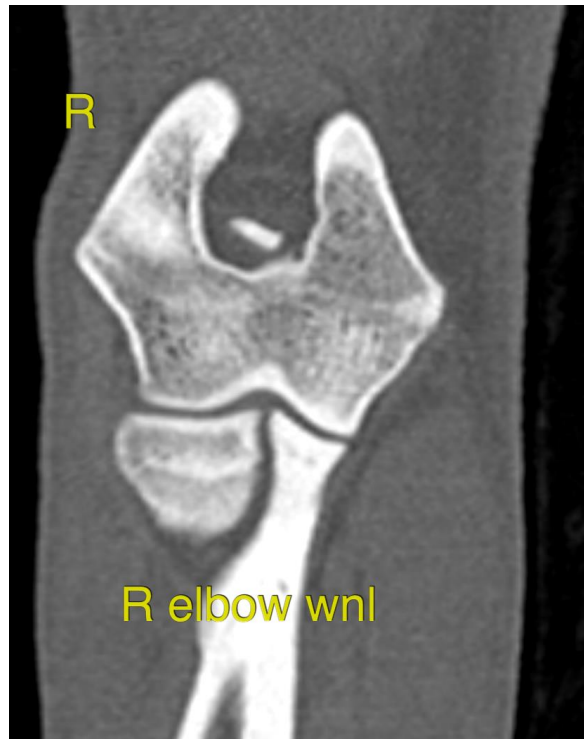
Dr. Jeffery Biskup

INVOICE

52144

DATE

5-14-22





PATIENT

Casper Rependa

The information and recommendations provided are based on the images presented by the referring veterinarian/sonographer. No evaluation can be communicated regarding pathology that was not visible in the image/video clips provided.

SPECIES

Canine

Thank you for this referral. If the clinical or image interpretation does not parallel your findings or if I can be of any further assistance please contact me.

BREED

Golden Retriever

Nele Eley, DVM, Dr. med. vet., DipECVDI
European Specialist in Veterinary Diagnostic Imaging, Cert. Radiology,
Senior lecturer University of Giessen, Germany, Veterinary Faculty, Department of Radiology
Nele.Eley@sonopath.com

SEX

M

AGE

8 Months

INTERPRETED BY

Nele Eley, DVM
Dr. med. Vet. DipECVDI

HOSPITAL NAME

Animal Health
Partners

REFERRING VET

Dr. Jeffery Biskup

INVOICE

52144

DATE

5-14-22