



PATIENT

Ruby Rothemich

PRESENTING CLINICAL SIGNS

Ruby presented on 5/10/22 for generalized lethargy, inappetance and reduced water in take. 1 soft stool episode on 5/11/22. Xrays were ordered for initial eval, however upon minimal improvement to symptomatic therapy with nausea meds. Rad review was ordered
Abnormal PE/Chem/CBC/UA Results: ALT 124, all else wnl

SPECIES

Canine

RADIOGRAPHIC STUDY OF THE THORAX & ABDOMEN

Right/left lateral and ventrodorsal views totaling 7 images available for review.

BREED

Standard Poodle

RADIOGRAPHIC FINDINGS

Thorax

Mild to moderate spondyloses are present between T4/5, T5/6, T9/10, and T12/13.

SEX

FS

The degree of pulmonary inflation is deep. A moderate generalized bronchial lung pattern with occasional peripheral cylindrical bronchiectasis is seen.

AGE

11

The radiographic presentation of the cardiac silhouette is within normal limits. No specific chamber enlargement is seen. The pulmonary vasculature presents within normal limits. The vertebral heart score is 8.6.

INTERPRETED BY

Nele Eley, DVM
Dr. med. Vet. DipECVDI

Mild esophageal aerophagia is seen and considered incidental.

Course and width of the trachea are considered within normal limits.

There is no evidence of abnormal mediastinal widening.

HOSPITAL NAME

Golden Isles Animal
Hospital

Abdomen

Moderate spondylosis deformans is present between L2 and L3. Lumbosacral spondylosis deformans is seen as well.

The abdominal serosal detail is maintained.

REFERRING VET

James Hornbuckle

The stomach contains a mild amount of gas.

The small intestinal loops are evenly distributed throughout the mid abdomen without evidence of abnormal dilation, plication, or radiopaque foreign material.

INVOICE

52118

The liver, kidneys, and visible parts of the spleen present within normal limits.

The urinary bladder presents within normal limits.

DATE

5-12-22

RADIOGRAPHIC DIAGNOSIS

- Mild bronchial lung pattern.
- No radiographic evidence of gastrointestinal ileus.
- Normal radiographic presentation of the cardiac silhouette.



PATIENT

Ruby Rothemich

- Multiple spondyloses.

INTERPRETATION OF THE FINDINGS & FURTHER RECOMMENDATIONS

The radiographic study reveals no evidence of pulmonary masses or nodules. The cardiovascular system presents within normal limits.

SPECIES

Canine

No abdominal organomegaly or reduced serosal detail is seen. There is no radiographic evidence of mechanical ileus.

BREED

Standard Poodle

SEX

FS

AGE

11

INTERPRETED BY

Nele Eley, DVM
Dr. med. Vet. DipECVDI

HOSPITAL NAME

Golden Isles Animal
Hospital

REFERRING VET

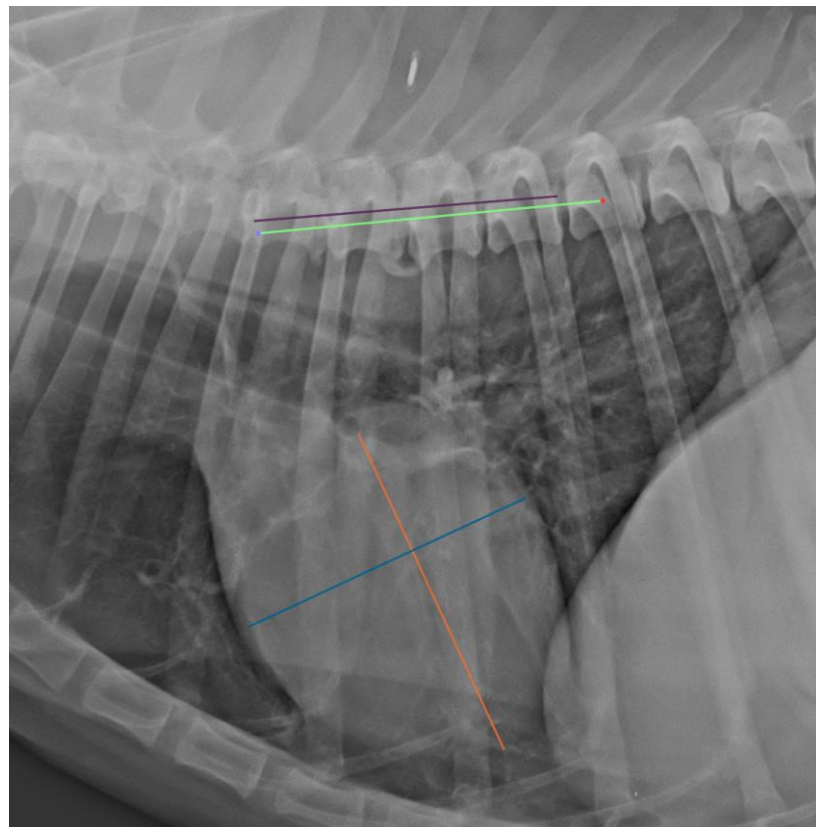
James Hornbuckle

INVOICE

52118

DATE

5-12-22



The information and recommendations provided are based on the images presented by the referring veterinarian/sonographer. No evaluation can be communicated regarding pathology that was not visible in the image/video clips provided.

Thank you for this referral. If the clinical or image interpretation does not parallel your findings or if I can be of any further assistance please contact me.

Nele Eley, DVM, Dr. med. vet., DipECVDI
European Specialist in Veterinary Diagnostic Imaging, Cert. Radiology,
Senior lecturer University of Giessen, Germany, Veterinary Faculty, Department of Radiology
Nele.Eley@sonopath.com