



PATIENT

Bella Moon Miranda

PRESENTING CLINICAL SIGNS

has been sneezing for the past 3 weeks with nasal discharge tinged with blood , snoring and nasal congestion was on temarle and clavamox which didn't do any good doing well otherwise eating drinking normal no vomiting or diarrhea

SPECIES

Abnormal PE/Chem/CBC/UA Results: cbc,chem , u/a : all wnl chest xray : all normal abdominal ultrasound : wnl

Canine

RADIOGRAPHIC STUDY OF THE HEAD

BREED

Lateral and oblique dorsoventral views totaling 4 images available for review.

Beagle

RADIOGRAPHIC FINDINGS

SEX

There appears to be increased soft tissue opacity within the nasal cavities with reduced visibility or the nasal turbinates and conchae. No clear aggressive osteolytic changes of the paranasal bones is seen. The lumen of the frontal sinuses appears to be reduced due to shortening of the facial bones.

FS

The dentition is incomplete.

AGE

RADIOGRAPHIC DIAGNOSIS

8 Years

- Suspect nasal turbinate destruction.

INTERPRETED BY

Nele Eley, DVM
Dr. med. Vet. DipECVDI

INTERPRETATION OF THE FINDINGS & FURTHER RECOMMENDATIONS

The radiographic changes suggest nasal pathology with turbinate destruction such as chronic rhinitis with destructive component. However, soft tissue mass with aggressive biological behavior and turbinate destruction cannot be ruled out. Consider rhinoscopy with sampling for further definition ideally in combination with a CT study of the head.

HOSPITAL NAME

CJAH

REFERRING VET

Gabriel

INVOICE

52121

DATE

5-12-22



PATIENT

Bella Moon Miranda

SPECIES

Canine

BREED

Beagle

SEX

FS

AGE

8 Years

INTERPRETED BY

Nele Eley, DVM
Dr. med. Vet. DipECVDI

HOSPITAL NAME

CJAH

REFERRING VET

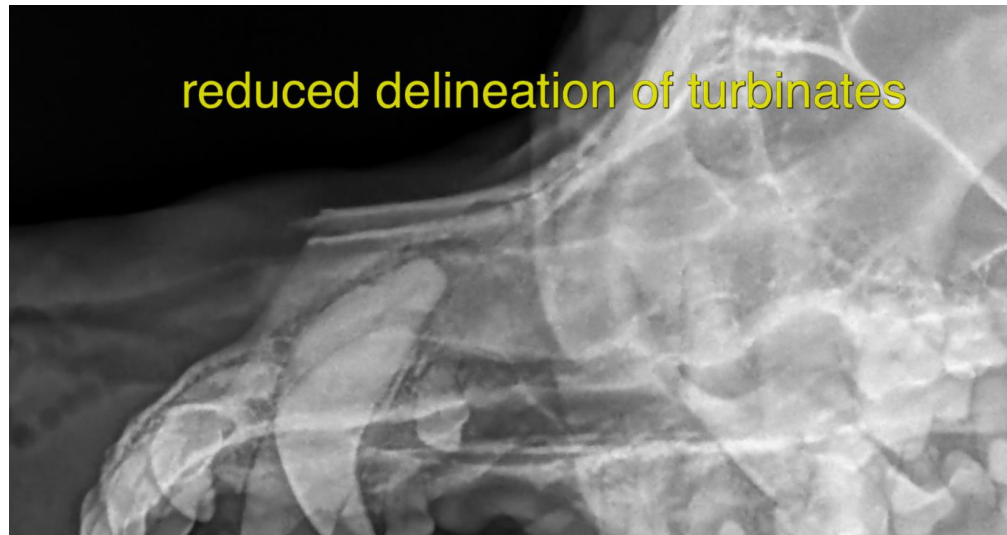
Gabriel

INVOICE

52121

DATE

5-12-22



The information and recommendations provided are based on the images presented by the referring veterinarian/sonographer. No evaluation can be communicated regarding pathology that was not visible in the image/video clips provided.

Thank you for this referral. If the clinical or image interpretation does not parallel your findings or if I can be of any further assistance please contact me.

Nele Eley, DVM, Dr. med. vet., DipECVDI
European Specialist in Veterinary Diagnostic Imaging, Cert. Radiology,
Senior lecturer University of Giessen, Germany, Veterinary Faculty, Department of Radiology
Nele.Eley@sonopath.com