



PATIENT PRESENTING CLINICAL SIGNS

Luna London avulsion fracture of the left knee. Cranial drawer elicited on exam. bilateral cruciate scan performed.

SPECIES ULTRASONOGRAPHIC FINDINGS

Canine **Left Stifle**

Moderate anechoic effusion is seen within the supra- and infra-patellar recesses of the left stifle joint. The cranial cruciate ligament presents continuous and well delineated. No evidence of rupture is seen. The lateral and medial meniscus present in situ and within normal limits.

BREED

Pitbull The avulsion fracture is not part of the scan.

SEX Right Stifle

F intact No abnormal effusion is seen within the supra- and infra patellar area. There is no evidence of synovial or capsular thickening or proliferation. The cranial cruciate ligament appears to be continuous and well-delineated, no deviation from normal echoarchitecture is noted. Lateral and medial menisci are within their anticipated positions and align well below the bone surfaces, meniscal surfaces are even and smooth. The echotexture is hypo echoic and uniform. The joint margins are smooth, no osteophytes are seen. The infra patellar fat pad present, the expected echo architecture.

AGE

6 Months

INTERPRETED BY ULTRASONOGRAPHIC DIAGNOSIS

Nele Eley, DVM
Dr. med. Vet. DipECVDI

- Moderate effusion of the left stifle joint in conjunction with trauma and avulsion fracture of the tibial tuberosity.
- Intact left cranial cruciate ligament.
- Normal left medial and lateral menisci.
- Normal right stifle joint.

HOSPITAL NAME

All Creatures G&S
Denville

INTERPRETATION OF THE FINDINGS & FURTHER RECOMMENDATIONS

The ultrasonographic findings do not support presence of concurrent cranial cruciate ligament injury in the affected left stifle. The lax feel may be a combination of an immature knee where mild laxity can be a normal finding with the avulsion fracture and at this time I do not consider rupture of the cranial cruciate ligament a likely potential. No evidence of meniscal injury is seen.

REFERRING VET

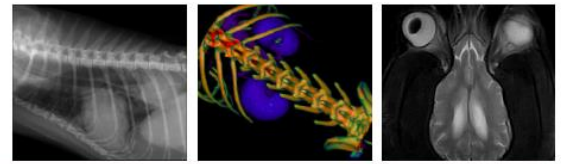
Dr. Mitrovic

INVOICE

58228

DATE

5-11-23



PATIENT

Luna London

SPECIES

Canine

BREED

Pitbull

SEX

F intact

AGE

6 Months

INTERPRETED BY

Nele Eley, DVM
Dr. med. Vet. DipECVDI

HOSPITAL NAME

All Creatures G&S
Denville

REFERRING VET

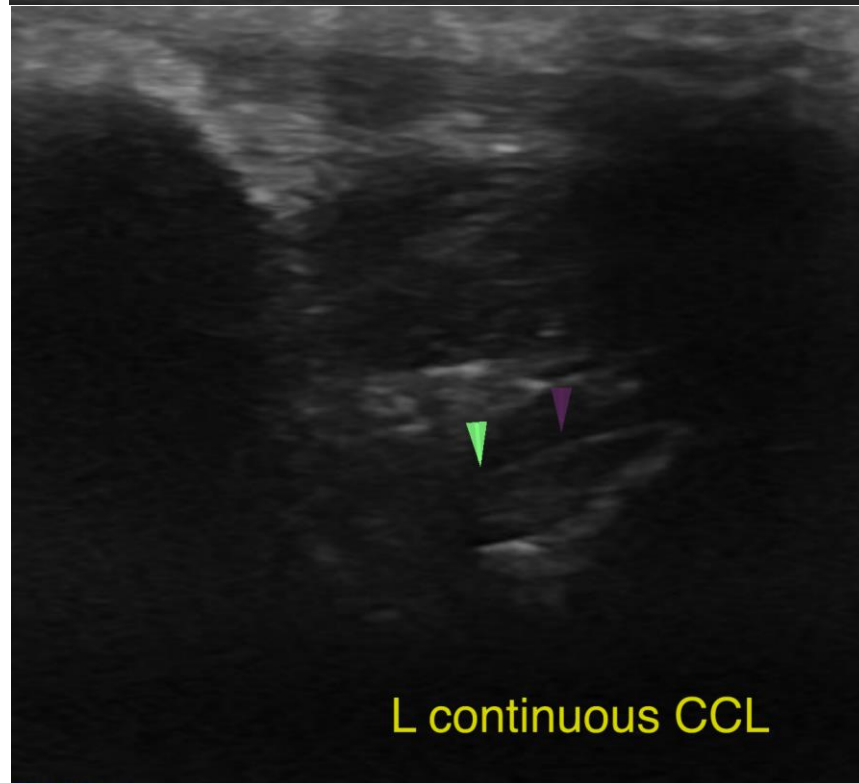
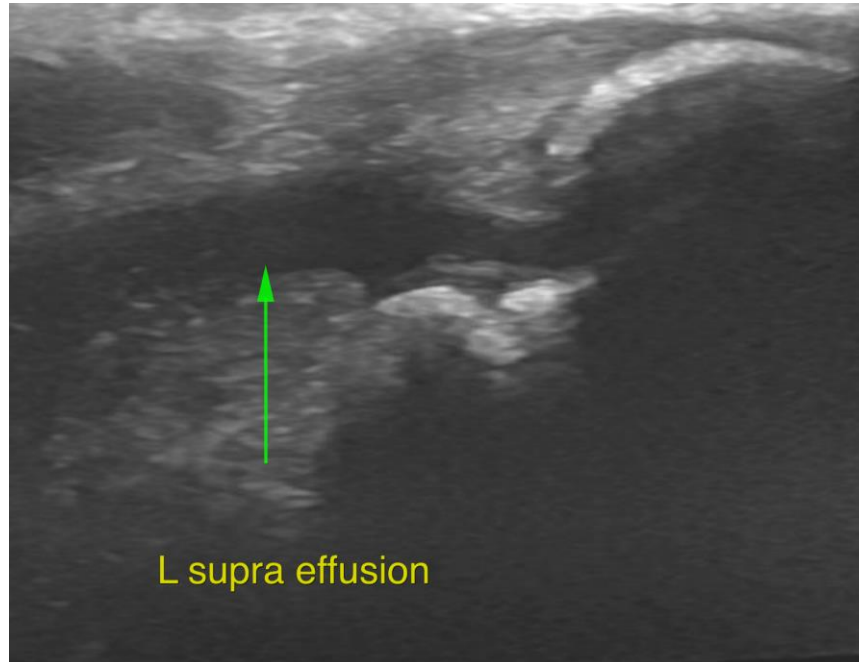
Dr. Mitrovic

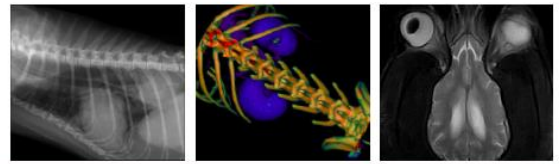
INVOICE

58228

DATE

5-11-23





PATIENT

Luna London

The information and recommendations provided are based on the images presented by the referring veterinarian/sonographer. No evaluation can be communicated regarding pathology that was not visible in the image/video clips provided.

SPECIES

Canine

Thank you for this referral. If the clinical or image interpretation does not parallel your findings or if I can be of any further assistance please contact me.

Nele Eley, DVM, Dr. med. vet., DipECVDI
European Specialist in Veterinary Diagnostic Imaging, Cert. Radiology,
Senior lecturer University of Giessen, Germany, Veterinary Faculty, Department of Radiology
Nele.Eley@sonopath.com

BREED

Pitbull

SEX

F intact

AGE

6 Months

INTERPRETED BY

Nele Eley, DVM
Dr. med. Vet. DipECVDI

HOSPITAL NAME

All Creatures G&S
Denville

REFERRING VET

Dr. Mitrovic

INVOICE

58228

DATE

5-11-23