



**PATIENT PRESENTING CLINICAL SIGNS**

Rocky Vincent Sudden onset of vomiting, lethargy, hiding and yelling. No history of urinary tract issues, owner said urinated well yesterday. Uncomfortable on palpation around bladder. Stones?

**SPECIES RADIOGRAPHIC STUDY OF THE ABDOMEN**

Feline Right/left lateral and ventrodorsal whole body views totaling 3 images provided for review. Abdominal read only requested.

**BREED RADIOGRAPHIC FINDINGS**

Persian X Wet fur artifact is noted.

**SEX**

Neutered Male

The urinary bladder is severely distended. Three small, ovoid, radiopaque calculi superimpose onto the urinary bladder. There is one mineral opaque structure superimposed onto the right kidney. The right kidney is larger than the left kidney. The left kidney is small and presents surface irregularity with lateral concavity.

**AGE**

13 Years

The abdominal serosal detail is reduced and there is heterogeneous increase in opacity of the mesentery in the ventral abdomen.

**RADIOGRAPHIC DIAGNOSIS**

- Reduced serosal detail
- Distended urinary bladder with at least three radiopaque urinary bladder calculi
- Bilateral nephropathy with small renal calculus of the right kidney and suspect chronic nephropathy of the left kidney with right-sided hypertrophy.

**INTERPRETED BY**

Nele Eley (Ondreka),  
DVM Dr. med. vet.,  
DipECVDI

**INTERPRETATION OF FINDINGS & FURTHER RECOMMENDATIONS**

The radiographic study suggests the presence of small amounts of peritoneal effusion or peritonitis. The urinary bladder is severely distended and urinary bladder calculi are seen. Lower urinary tract obstruction with rupture or secondary peritonitis is one potential underlying cause. However, other underlying pathology cannot be ruled out entirely, and further definition by means of retrograde catheterization to rule out lower urinary tract obstructive pathology, as well as abdominal ultrasound and urinalysis, are recommended if not already performed.

**HOSPITAL NAME**

Sunridge Vet Clinic

**REFERRING VET**

Dr. Alanah

**INVOICE**

37580

**DATE**

5/10/22



**PATIENT**

Rocky Vincent

**SPECIES**

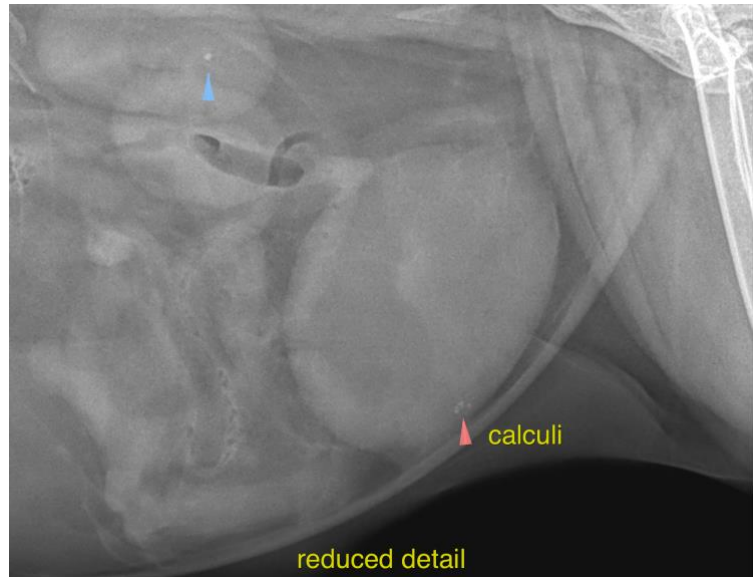
Feline

**BREED**

Persian X

**SEX**

Neutered Male



**AGE**

13 Years

The information and recommendations provided are based on the images presented by the referring veterinarian. No evaluation can be communicated regarding pathology that was not visible in the image/video clips provided.

Thank you for this referral. If the clinical or image interpretation does not parallel your findings or if I can be of any further assistance please contact me.

**INTERPRETED BY**

Nele Eley (Ondreka),  
DVM Dr. med. vet.,  
DipECVDI

**Nele Eley (Ondreka)**, DVM, Dr. med. vet., DipECVDI  
European Specialist in Veterinary Diagnostic Imaging, Cert. Radiology,  
Senior lecturer University of Giessen/Germany, Veterinary Faculty, Department of Radiology.  
Nele.Eley@sonopath.com

**HOSPITAL NAME**

Sunridge Vet Clinic

**REFERRING VET**

Dr. Alanah

**INVOICE**

37580

**DATE**

5/10/22