



PATIENT PRESENTING CLINICAL SIGNS

Mica Prieto UNDERWEIGHT, HX OF GIARDIA INTERMITTENT REGURGITATION, VOMITING.
 Abnormal PE/Chem/CBC/UA Results: CBC: WNL CHEM : ALKP 186 (20-150) BUN 47(7-25)
 PHOSP 9.5 (2.9-6.8) TP 5.3(5.4-8.2) GLOB 1.3(2.3-5.2) GIARDIA AND FECAL NEGATIVE

SPECIES RADIOGRAPHIC STUDY OF THE THORAX & ABDOMEN

Canine Lateral view of the neck and lateral and ventrodorsal views of the thorax and abdomen totaling 5 images available for review.

BREED RADIOGRAPHIC FINDINGS

Boston Terrier The patient is skeletally immature.

SEX Thorax

Female Mild esophageal aerophagia is noted; however, there is no evidence of generalized abnormal dilation of the esophagus and no evidence of aspiration pneumonia is noted.

AGE The radiographic presentation of the cardiac silhouette and bronchopulmonary structures is considered within age related normal limits.

6 Months **Abdomen**

INTERPRETED BY The abdominal serosal detail is minimally reduced which is in concordance with the patient age and the presence of brown fat.

Nele Eley, DVM
 Dr. med. Vet. DipECVDI

Mild dilation of the stomach with gas is seen consistently on all available images.

HOSPITAL NAME The small intestinal loops are evenly distributed throughout the mid abdomen with no evidence of abnormal dilation, plication, or radiopaque foreign material.

Sunset Animal Hospital The colon presents within normal limits.

The kidneys and urinary bladder present within normal limits as well.

REFERRING VET RADIOGRAPHIC DIAGNOSIS

- Cristina Polit
- No radiographic evidence of megaesophagus or hiatal hernia.
 - Gastric maldigestion pattern.

INVOICE INTERPRETATION OF THE FINDINGS & FURTHER RECOMMENDATIONS

52116 The radiographic study is negative for abnormal esophageal dilation. Esophageal dysmotility, gastroesophageal reflux, and intermittent/sliding hernia cannot be ruled out entirely.

DATE The gastric dilation with air may be due to aerophagia; however, gastritis/gastroenteritis, hypertrophic pyloric gastropathy, or functional ileus cannot be ruled out and further definition by means of abdominal ultrasound and/or endoscopy could be considered if not performed already depending on the clinical course of the disease.

5-11-22



PATIENT

Mica Prieto

SPECIES

Canine

BREED

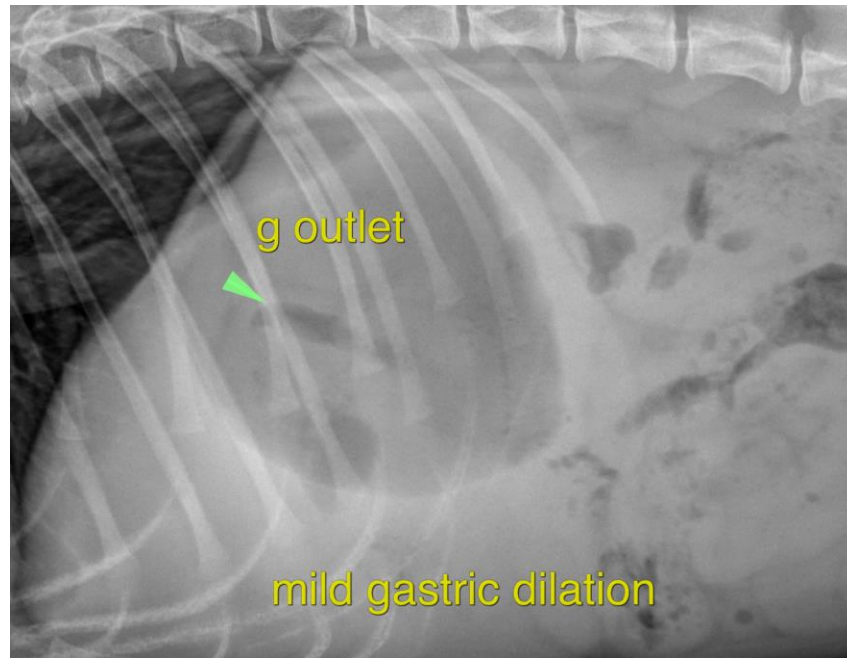
Boston Terrier

SEX

Female

AGE

6 Months



INTERPRETED BY

Nele Eley, DVM
Dr. med. Vet. DipECVDI

The information and recommendations provided are based on the images presented by the referring veterinarian/sonographer. No evaluation can be communicated regarding pathology that was not visible in the image/video clips provided.

HOSPITAL NAME

Sunset Animal
Hospital

Thank you for this referral. If the clinical or image interpretation does not parallel your findings or if I can be of any further assistance please contact me.

Nele Eley, DVM, Dr. med. vet., DipECVDI
European Specialist in Veterinary Diagnostic Imaging, Cert. Radiology,
Senior lecturer University of Giessen, Germany, Veterinary Faculty, Department of Radiology
Nele.Eley@sonopath.com

REFERRING VET

Cristina Polit

INVOICE

52116

DATE

5-11-22