



**PATIENT PRESENTING CLINICAL SIGNS**

**Gunner Gray** Acute bleeding from the left nostril. Has been controlled last 3 days with epinephrine splash. Blood clotting time & platelet counts are normal.

**SPECIES** Abnormal PE/Chem/CBC/UA Results: Elevated Alk Phos & ALT on bloodwork today, all other values within normal limits; CBC within normal limits. Heavy tartar build-up on teeth, otherwise normal PE.

Canine

**COMPUTED TOMOGRAPHIC STUDY OF THE HEAD**

**BREED** Plain and post contrast studies available for review.

**Golden Retriever COMPUTED TOMOGRAPHIC FINDINGS**

**SEX** The brain presents no deviation from normal anatomy and symmetry. The grey and white matter distinction and the neuroparenchymal attenuation are as expected. The distribution of contrast enhancement is within normal limits throughout the parenchyma and meninges. The ventricular system is non-dilated and within the limits of the expected volume and symmetry.

Male

**AGE** The number and folding of the nasal turbinates present within normal limits. There is no evidence of turbinate destruction or a nasal soft tissue mass. The frontal sinuses present within normal limits. A mild amount of fluid attenuating material is seen within the left nasal cavity and left maxillary recess. No evidence of significant dental disease is noted despite multiple dental plaques and resorptive changes of the tooth roots.

12 Years

**INTERPRETED BY** Both temporomandibular joints present congruent joint spaces with even subchondral bone surfaces and are considered within normal limits.

Nele Eley, DVM  
Dr. med. Vet. DipECVDI

Both tympanic bullae are aerated, the mucosal lining is not seen, the bony wall is smooth and thin. The external auditory meatuses present within normal limits.

**HOSPITAL NAME** The submandibular and medial retropharyngeal lymph nodes are small and elongated with a normal short-to-long-axis-ratio is < 0.5, the attenuation and contrast enhancement pattern is uniform.

Casselton Vet Service

The salivary glands present within normal limits.

**REFERRING VET COMPUTED TOMOGRAPHIC DIAGNOSIS**

Laurie Huckle

- Mild fluid accumulation within the left nasal cavity and left maxillary recess with no structural nasal pathology seen.

**INVOICE INTERPRETATION OF THE FINDINGS & FURTHER RECOMMENDATIONS**

58235

The CT study does not reveal evidence of nasal foreign material, relevant dental disease, destructive rhinitis, or a soft tissue mass. Systemic hypertension, coagulopathy, and paraneoplastic syndrome are primary differential diagnoses.

**DATE**

5-10-23

The mild fluid attenuating material within the left nasal cavity and left maxillary recess is likely to represent blood.



**PATIENT**

Gunner Gray

**SPECIES**

Canine

**BREED**

Golden Retriever

**SEX**

Male

**AGE**

12 Years

**INTERPRETED BY**

Nele Eley, DVM  
Dr. med. Vet. DipECVDI

**HOSPITAL NAME**

Casselton Vet Service

**REFERRING VET**

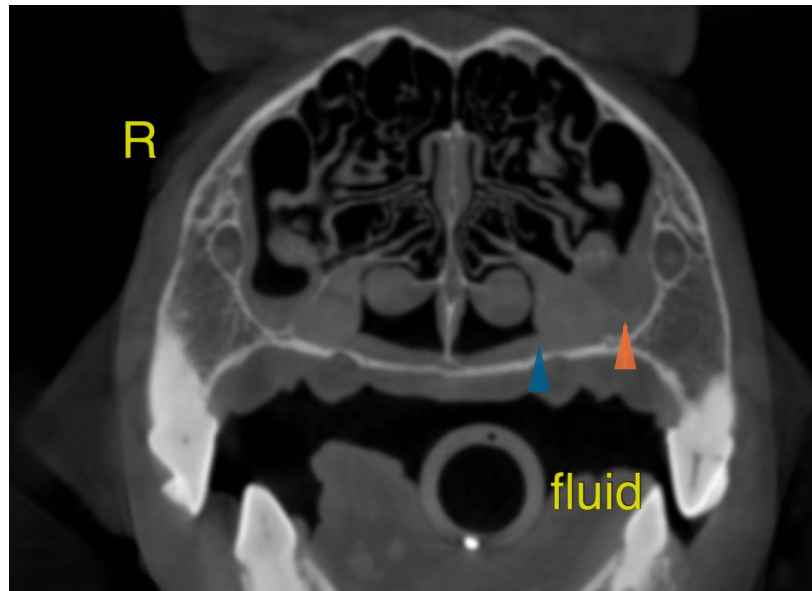
Laurie Huckle

**INVOICE**

58235

**DATE**

5-10-23



The information and recommendations provided are based on the images presented by the referring veterinarian/sonographer. No evaluation can be communicated regarding pathology that was not visible in the image/video clips provided.

Thank you for this referral. If the clinical or image interpretation does not parallel your findings or if I can be of any further assistance please contact me.

**Nele Eley**, DVM, Dr. med. vet., DipECVDI  
European Specialist in Veterinary Diagnostic Imaging, Cert. Radiology,  
Senior lecturer University of Giessen, Germany, Veterinary Faculty, Department of Radiology  
Nele.Eley@sonopath.com