



PATIENT

Louis Watts

PRESENTING CLINICAL SIGNS

Vomiting (on/off), eating this morning Hospitalized for 48 hrs.
Abnormal PE/Chem/CBC/UA Results: Pancreatitis

SPECIES

Canine

RADIOGRAPHIC STUDY OF THE ABDOMEN

Right/left lateral and ventrodorsal views totaling 4 images available for review.

BREED

Shih Tzu

RADIOGRAPHIC FINDINGS

Reduced serosal detail is not explicitly seen however the crowding of the gastrointestinal tract interferes with the assessment of which.

A rounded structure is superimposed onto the ventrocaudal margin of the liver and likely to represent the distended gallbladder.

SEX

Male Neuter

Small mineral opaque foci appear to superimpose onto the left kidney in the orthogonal view.

The stomach is post-prandial.

AGE

7 Years

The small intestinal loops are evenly distributed throughout the mid abdomen. No evidence of abnormal dilation, plication, or radiopaque foreign material is seen.

INTERPRETED BY

Nele Eley, DVM
Dr. med. Vet. DipECVDI

RADIOGRAPHIC DIAGNOSIS

- Suspect distended gallbladder.
- No radiographic evidence of mechanical ileus.
- Potential for hypercalcemic nephropathy versus summation artifact.

HOSPITAL NAME

St. Catherine's Animal
Hospital

INTERPRETATION OF THE FINDINGS & FURTHER RECOMMENDATIONS

Rounded lobar margin of the liver versus distended gallbladder is suggested by the radiographic findings.

Further definition by means of abdominal ultrasound could be considered in case of persistent clinical signs and to rule out hepatic lobar origin as well as mucocele, cholecystitis, or other.

REFERRING VET

Dr. Masoud

INVOICE

52045

DATE

5-10-22



PATIENT

Louis Watts

SPECIES

Canine

BREED

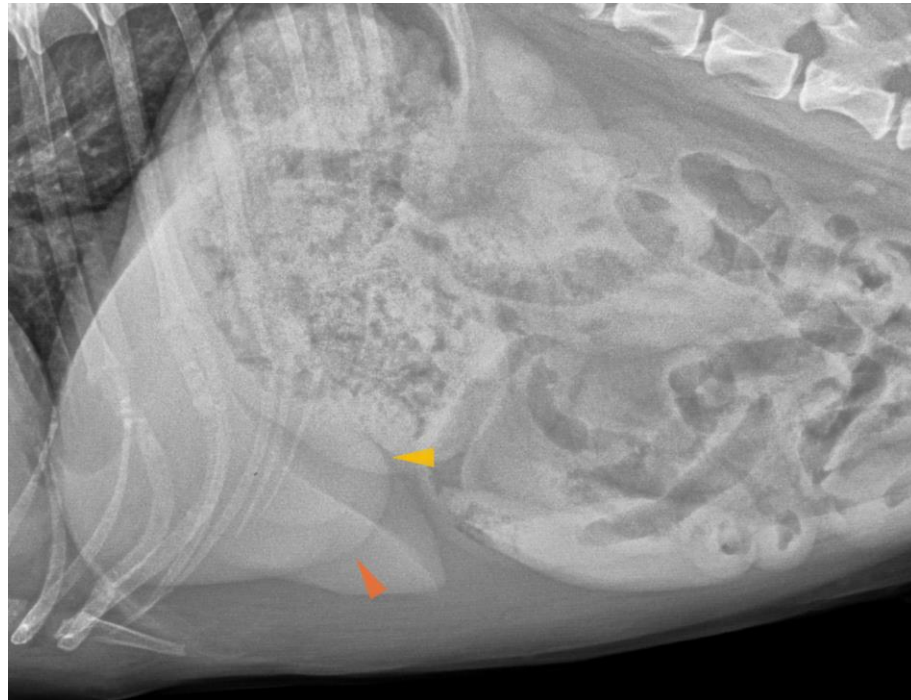
Shih Tzu

SEX

Male Neuter

AGE

7 Years



INTERPRETED BY

Nele Eley, DVM
Dr. med. Vet. DipECVDI

The information and recommendations provided are based on the images presented by the referring veterinarian/sonographer. No evaluation can be communicated regarding pathology that was not visible in the image/video clips provided.

Thank you for this referral. If the clinical or image interpretation does not parallel your findings or if I can be of any further assistance please contact me.

HOSPITAL NAME

St. Catherine's Animal
Hospital

Nele Eley, DVM, Dr. med. vet., DipECVDI
European Specialist in Veterinary Diagnostic Imaging, Cert. Radiology,
Senior lecturer University of Giessen, Germany, Veterinary Faculty, Department of Radiology
Nele.Eley@sonopath.com

REFERRING VET

Dr. Masoud

INVOICE

52045

DATE

5-10-22