



PATIENT

Lola Vanderzanden

PRESENTING CLINICAL SIGNS

Difficulty breathing, grade3/6 mitral valve murmur. Harsh lungs left side dysmic.

SPECIES

Canine

RADIOGRAPHIC STUDY OF THE THORAX

Right/left lateral and ventrodorsal views totaling 3 images available for review.

BREED

Mini Poodle

RADIOGRAPHIC FINDINGS

Moderate left sided cardiomegaly with basal-apical enlargement of the cardiac silhouette and tracheal elevation is noted. The vertebral heart score is 12. The left atrium is enlarged. Left atrial tenting and a double opacity sign are seen. The auricular appendage of the left atrium is enlarged. Pulmonary venous dilation is noted.

SEX

Female/s

A mild diffuse interstitial pattern is seen within the perihilar region of the left caudal lung lobe. Mild increase in interstitial opacity appears to be present within the right, middle, and left cranial lung lobes as well.

AGE

11

RADIOGRAPHIC DIAGNOSIS

- Moderate left sided cardiomegaly with pulmonary venous hypertension and suspect incipient cardiogenic pulmonary edema.

INTERPRETED BY

Nele Eley, DVM
Dr. med. Vet. DipECVDI

INTERPRETATION OF THE FINDINGS & FURTHER RECOMMENDATIONS

The radiographic study reveals moderate left sided cardiomegaly with left atrial enlargement and dilation of the pulmonary veins suggesting pulmonary venous hypertension. The mild perihilar increase in interstitial opacity suggests potential for developing cardiogenic pulmonary edema. Consider chronic mitral valve regurgitation due to mitral valve endocardiosis a primary potential. However, a cardiac echo is recommended for detailed staging to rule out differential diagnoses and adjust the medial treatment accordingly.

HOSPITAL NAME

Pacific Avenue
Veterinary Clinic

REFERRING VET

Dr. Sid Bruckert-Frisk

INVOICE

52060

DATE

5-10-22



PATIENT

Lola Vanderzanden

SPECIES

Canine

BREED

Mini Poodle

SEX

Female/s

AGE

11

INTERPRETED BY

Nele Eley, DVM
Dr. med. Vet. DipECVDI

HOSPITAL NAME

Pacific Avenue
Veterinary Clinic

REFERRING VET

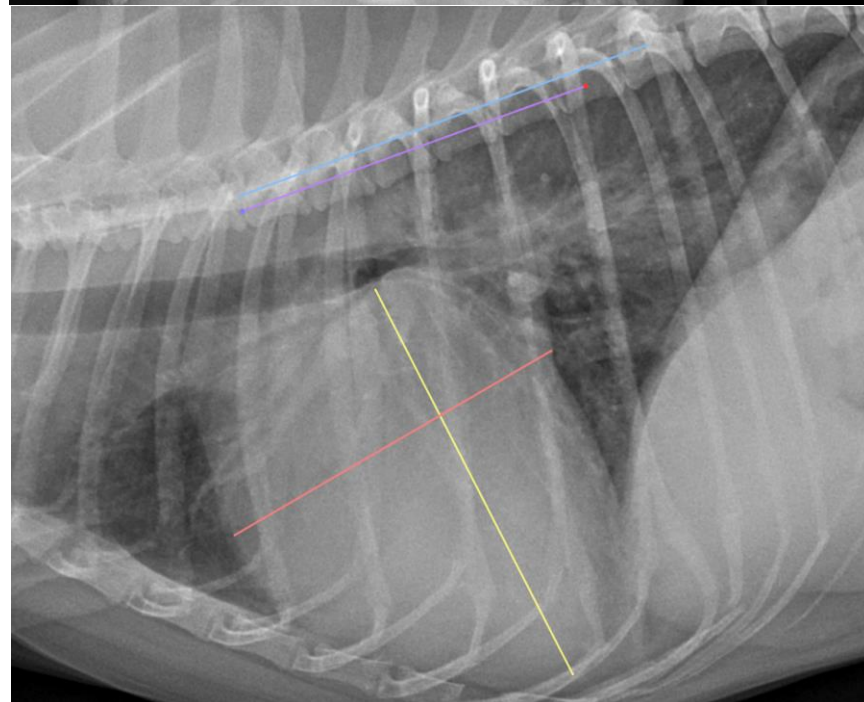
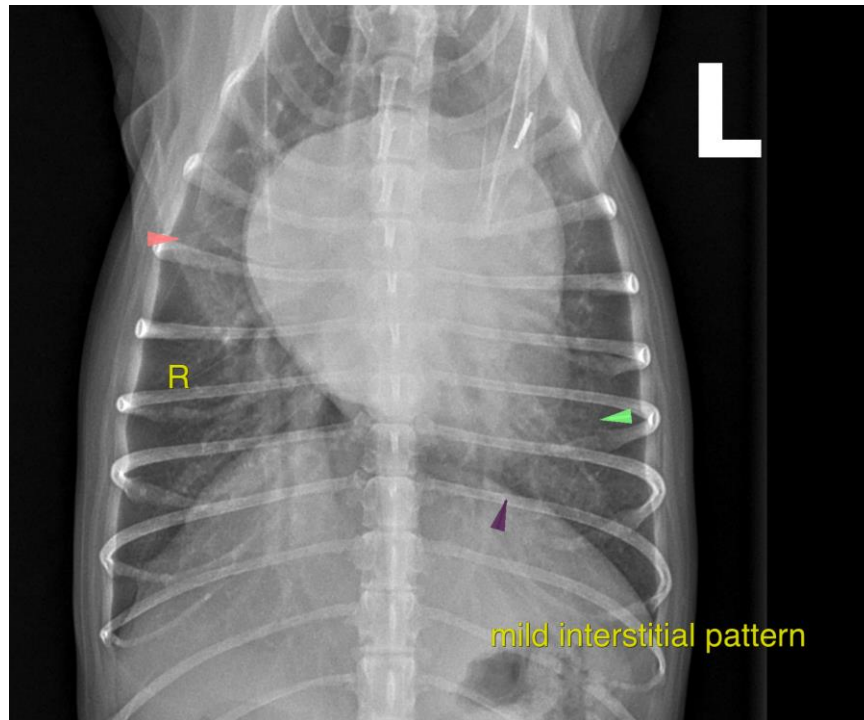
Dr. Sid Bruckert-Frisk

INVOICE

52060

DATE

5-10-22





PATIENT

Lola Vanderzanden

The information and recommendations provided are based on the images presented by the referring veterinarian/sonographer. No evaluation can be communicated regarding pathology that was not visible in the image/video clips provided.

Thank you for this referral. If the clinical or image interpretation does not parallel your findings or if I can be of any further assistance please contact me.

SPECIES

Canine

Nele Eley, DVM, Dr. med. vet., DipECVDI
European Specialist in Veterinary Diagnostic Imaging, Cert. Radiology,
Senior lecturer University of Giessen, Germany, Veterinary Faculty, Department of Radiology
Nele.Eley@sonopath.com

BREED

Mini Poodle

SEX

Female/s

AGE

11

INTERPRETED BY

Nele Eley, DVM
Dr. med. Vet. DipECVDI

HOSPITAL NAME

Pacific Avenue
Veterinary Clinic

REFERRING VET

Dr. Sid Bruckert-Frisk

INVOICE

52060

DATE

5-10-22