



PATIENT

Jasmine Lynch

PRESENTING CLINICAL SIGNS

q,d,r; bcs 4; ou cataracts; teethless; tongue extended; hypothermic (98.4), neurologic w/decreased r sided proprio, firm spongy abdomen; grade iv mpl's l> r with angular limb valgus of hind legs; other aspects of exam wnl's muscle convulsions seizure activity - lasting approx. 30 sec to 1-2 minutes r/o idiopathic epilepsy vs neoplasia (brain tumor) vs infectious/inflammatory vs hypoglycemia vs other

SPECIES

Canine

COMPUTED TOMOGRAPHIC STUDY OF THE HEAD

BREED

Morkie

Plain and post contrast studies in soft tissue and bones windows available for review.

COMPUTED TOMOGRAPHIC FINDINGS

SEX

Female Spayed

All teeth have been removed. Severe atrophy of the alveolar crest is seen in all quadrants. There is rostral mandibular symphysiolysis with severe bone atrophy. One mandibular incisor appears to be remaining and situated within the remaining gingivostomal soft tissues.

The middle and inner ear present within normal limits.

AGE

12 Years

No evidence of structural brain changes is seen. There is mild generalized ventriculomegaly without evidence of active distension of the ventricular system. No pathological contrast enhancement is noted.

Focal mineralization of the left external lens capsule is seen in the equator region of the lens.

INTERPRETED BY

Nele Eley, DVM
Dr. med. Vet. DipECVDI

COMPUTED TOMOGRAPHIC DIAGNOSIS

- Structurally normal CT study of the brain with mild ventriculomegaly.
- Incomplete dentition with severe atrophy of the alveolar crest and mandibular symphysiolysis.

HOSPITAL NAME

Westwood Regional
Veterinary Hospital

INTERPRETATION OF THE FINDINGS & FURTHER RECOMMENDATIONS

The CT study reveals no evidence of structural brain pathology. Primary / cryptogenic epilepsy, metabolic/toxic, neurodegenerative, and inflammatory/infectious disease cannot be ruled out entirely. Complementary csf analysis could be considered and correlation with laboratory values is required.

REFERRING VET

Goldman

INVOICE

52058

DATE

5-10-22



PATIENT

Jasmine Lynch

SPECIES

Canine

BREED

Morkie

SEX

Female Spayed

AGE

12 Years

INTERPRETED BY

Nele Eley, DVM
Dr. med. Vet. DipECVDI

HOSPITAL NAME

Westwood Regional
Veterinary Hospital

REFERRING VET

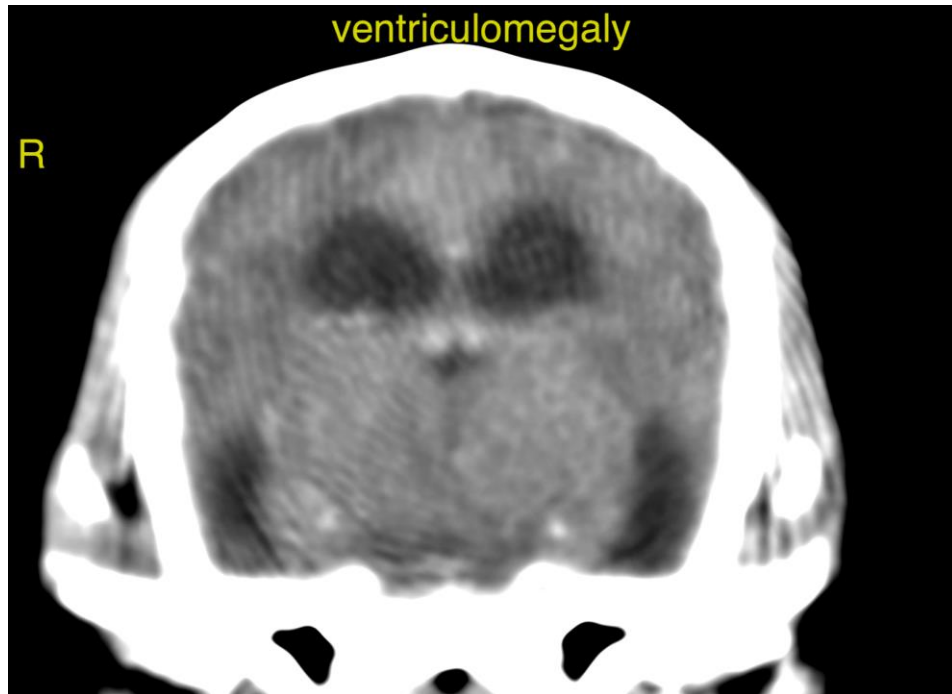
Goldman

INVOICE

52058

DATE

5-10-22



The information and recommendations provided are based on the images presented by the referring veterinarian/sonographer. No evaluation can be communicated regarding pathology that was not visible in the image/video clips provided.

Thank you for this referral. If the clinical or image interpretation does not parallel your findings or if I can be of any further assistance please contact me.

Nele Eley, DVM, Dr. med. vet., DipECVDI
European Specialist in Veterinary Diagnostic Imaging, Cert. Radiology,
Senior lecturer University of Giessen, Germany, Veterinary Faculty, Department of Radiology
Nele.Eley@sonopath.com