

**PATIENT**

Hercules Heuston

**PRESENTING CLINICAL SIGNS**

Grade 3/6 left sided murmur, Tachycardia/dysmia, coughing. Dysmia 6 plus months

**SPECIES**

Canine

**RADIOGRAPHIC STUDY OF THE THORAX**

Right/left lateral and ventrodorsal views totaling 4 images available for review.

**BREED**

Mix

T13/L1 and L1/2 as well as L2/3 spondylosis deformans is seen.

**SEX**

Male

Abundance of subcutaneous mediastinal and pericardial fat is noted.

**AGE**

10

There is mild esophageal aerophagia.

Course and width of the trachea are considered within normal limits.

The pulmonary volume is small. Multiple age related incidental pulmonary osteomas are seen. No significant changes of the bronchial tree or pulmonary interstitium are noted otherwise.

**INTERPRETED BY**

Nele Eley, DVM  
Dr. med. Vet. DipECVDI

The abdominal volume is large.

**RADIOGRAPHIC DIAGNOSIS**

- Small pulmonary volume and poor pulmonary inflation.
- Normal age related lung.
- Obesity.
- Normal radiographic presentation of the cardiac silhouette.
- Thoracolumbar spondyloses.

**HOSPITAL NAME**

Pacific Avenue  
Veterinary Clinic

**INTERPRETATION OF THE FINDINGS & FURTHER RECOMMENDATIONS**

Reduced inflation of the lung is present on all available images which likely due to the large abdominal volume and obesity. At this time, no significant bronchopulmonary changes and no radiographic evidence of cardiomegaly is seen which by no means rules out valvular insufficiencies, myocardial disease, and other cardiac pathology. However, there is no evidence of right or left sided congestive heart failure. A more detailed assessment may be achieved by a full cardiac echo if indicated based on the clinical signs.

**REFERRING VET**

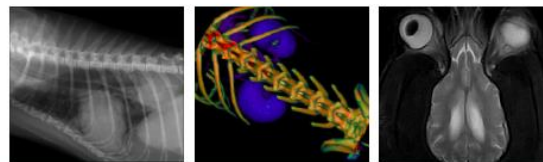
Dr. Sid Bruckert-Frisk

**INVOICE**

52059

**DATE**

5-10-22



**PATIENT**

Hercules Heuston

**SPECIES**

Canine

**BREED**

Mix

**SEX**

Male

**AGE**

10

**INTERPRETED BY**

Nele Eley, DVM  
Dr. med. Vet. DipECVDI

**HOSPITAL NAME**

Pacific Avenue  
Veterinary Clinic

**REFERRING VET**

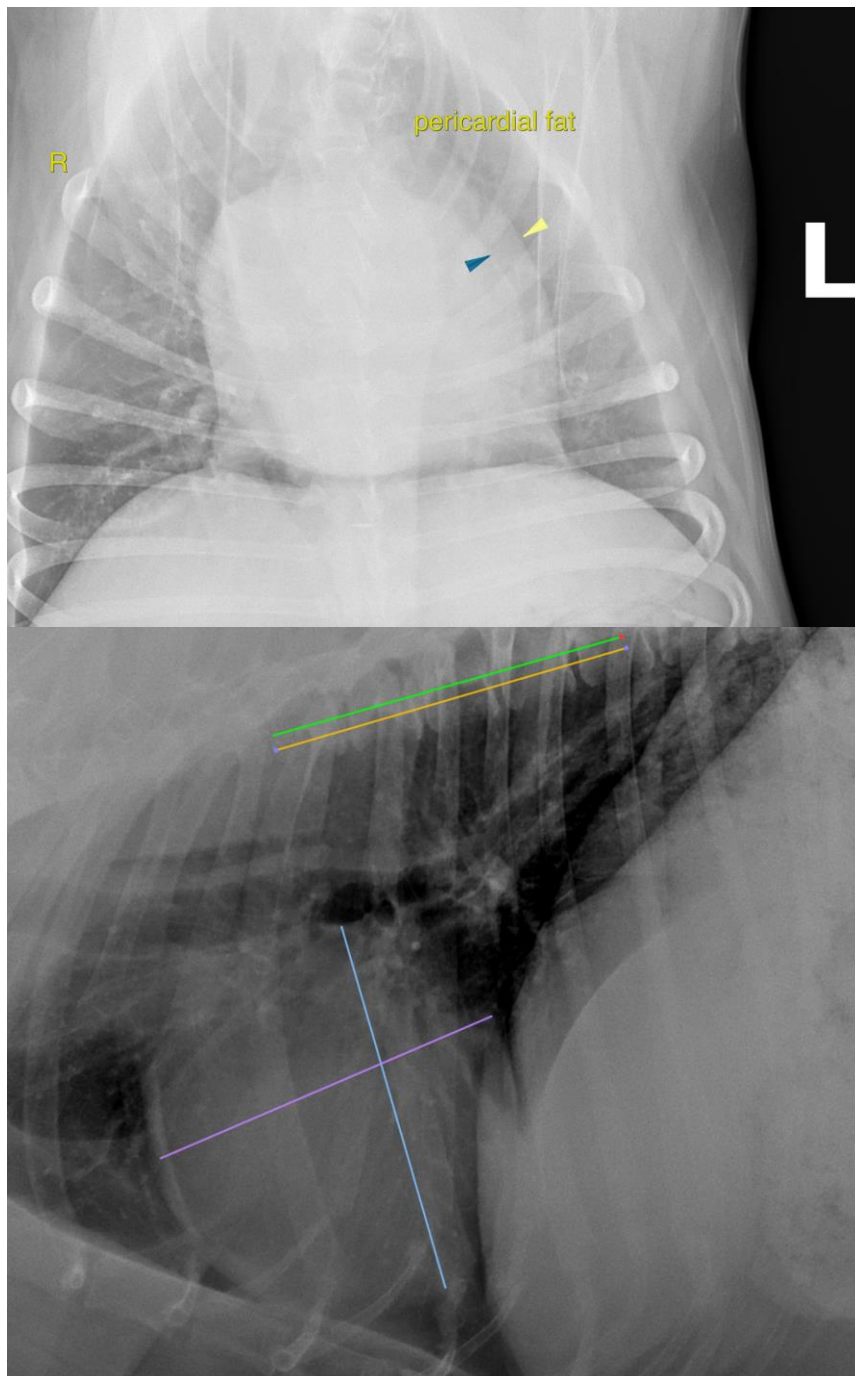
Dr. Sid Bruckert-Frisk

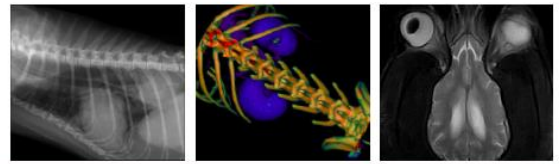
**INVOICE**

52059

**DATE**

5-10-22





**PATIENT**

Hercules Heuston

The information and recommendations provided are based on the images presented by the referring veterinarian/sonographer. No evaluation can be communicated regarding pathology that was not visible in the image/video clips provided.

**SPECIES**

Canine

Thank you for this referral. If the clinical or image interpretation does not parallel your findings or if I can be of any further assistance please contact me.

**BREED**

Mix

**Nele Eley**, DVM, Dr. med. vet., DipECVDI  
European Specialist in Veterinary Diagnostic Imaging, Cert. Radiology,  
Senior lecturer University of Giessen, Germany, Veterinary Faculty, Department of Radiology  
Nele.Eley@sonopath.com

**SEX**

Male

**AGE**

10

**INTERPRETED BY**

Nele Eley, DVM  
Dr. med. Vet. DipECVDI

**HOSPITAL NAME**

Pacific Avenue  
Veterinary Clinic

**REFERRING VET**

Dr. Sid Bruckert-Frisk

**INVOICE**

52059

**DATE**

5-10-22