



PATIENT PRESENTING CLINICAL SIGNS

PATIENT Gabby Kinney
SPECIES Pet was referred for imaging to determine the surgical feasibility of removal of a large cranial abdominal mass. Mass was initially found about 5 mos ago but pet was asymptomatic. Now pet is losing weight, initially was polyphagic, but is now hyporexic and V+ intermittently. Abnormal PE/Chem/CBC/UA Results: ALT 207 (10-100). ALP 419 (6-102). TBili 8.3 (0.1-0.4) CBC and electrolytes WNL

Feline

COMPUTED TOMOGRAPHIC STUDY OF THE ABDOMEN

BREED Plain and post contrast studies available for review.

DLH COMPUTED TOMOGRAPHIC FINDINGS

SEX A severely dilated saccular fluid filled structure is seen in the cranial and mid abdomen. This structure measures approximately 15 cm in diameter and tapers down towards the liver to feed into the severely dilated branches of the extra- and intra-hepatic biliary system. The gallbladder cannot be seen separate from this large cystic structure. The margination is of moderate thickness with contrast enhancement. The center of the cavity is contrast negative and uniformly fluid attenuating. Mild peritoneal effusion is seen. Other than the severe intrahepatic biliary duct dilation, multiple hypoattenuating nodules are present within and scattered throughout the liver. The stomach and gastric outlet are deviated and compressed into the left dorsal abdomen. The common bile duct cannot be clearly delineated. No evidence of a mass or calculi is seen in the region of the common bile duct.

AGE 11 Years, 5 Months

INTERPRETED BY Mild generalized pancreatic enlargement is noted with a structure of 5mm diameter seen within the pancreas.

Nele Eley, DVM
 Dr. med. Vet. DipECVDI

The spleen, small intestinal loops, and abdominal lymph nodes present within normal limits.

HOSPITAL NAME Small mineral attenuating foci are seen within the renal sinus of both kidneys without evidence of obstruction or pyelectasia.

Wilson Veterinary Hospital

COMPUTED TOMOGRAPHIC DIAGNOSIS

- Severe cystic dilation of the intra- and extra-hepatic biliary system with multiple hepatic nodules.
- Peritoneal effusion.
- Bilateral hypercalcemic nephropathy.

REFERRING VET Outside Clinic

INTERPRETATION OF THE FINDINGS & FURTHER RECOMMENDATIONS

INVOICE The CT findings suggest severe generalized dilation of the biliary system. Consider multiple severe chronic cholangiohepatitis versus biliary cyst adenoma versus obstructive pathology (even though no reason for obstruction directly seen) as potential underlying causes.

52044

DATE I cannot identify one discrete mass that would be resectable in this patient, and I doubt the patient would benefit from surgical exploration other than to examine for the less likely potential of obstruction within the biliary system.

5-10-22 The peritoneal effusion may represent transudate, modified transudate, and exudate. Bile



PATIENT

Gabby Kinney

peritonitis is not necessarily considered likely based on the CT findings. The mass effect onto the caudal vena cava may cause congestion and transudate or modified transudate effusion. Consider aspiration and analysis of the fluid for further definition.

SPECIES

Feline

BREED

DLH

SEX

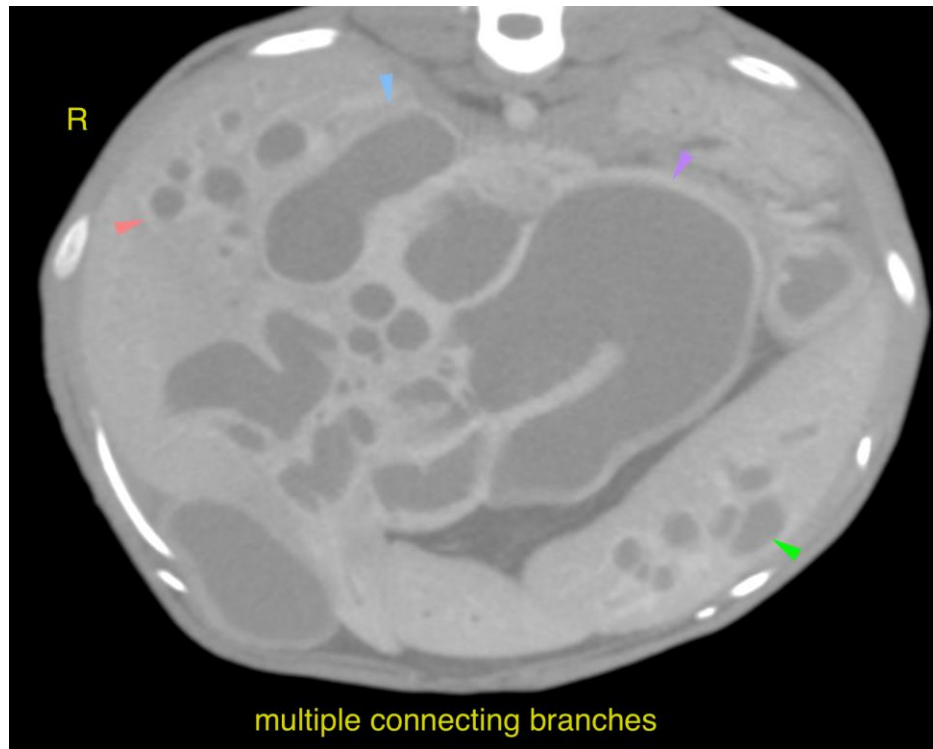
FS

AGE

11 Years, 5 Months

INTERPRETED BY

Nele Eley, DVM
Dr. med. Vet. DipECVDI



HOSPITAL NAME

Wilson Veterinary
Hospital

REFERRING VET

Outside Clinic

INVOICE

52044

DATE

5-10-22

The information and recommendations provided are based on the images presented by the referring veterinarian/sonographer. No evaluation can be communicated regarding pathology that was not visible in the image/video clips provided.

Thank you for this referral. If the clinical or image interpretation does not parallel your findings or if I can be of any further assistance please contact me.

Nele Eley, DVM, Dr. med. vet., DipECVDI
European Specialist in Veterinary Diagnostic Imaging, Cert. Radiology,
Senior lecturer University of Giessen, Germany, Veterinary Faculty, Department of Radiology
Nele.Eley@sonopath.com