

**PATIENT PRESENTING CLINICAL SIGNS**

Duffy Kolmer Presented 3/22 for lameness affecting Right forelimb. Swollen digit noted, radiographs taken (report attached). Hx of running on the beach often.  
Abnormal PE/Chem/CBC/UA Results: Hard, swollen digit Right forepaw.

**SPECIES COMPUTED TOMOGRAPHIC FINDINGS**

Canine **Front Paw**

**BREED**

Gordon Setter

The 3<sup>rd</sup> digit in what is marked the left front limb presents moderate soft tissue swelling circumferential to its proximal and middle phalanges. No evidence of foreign material can be identified. There is moderate brush bordered periosteal new bone formation associated with the diaphysis and distal metaphysis of the proximal phalanx in the 3<sup>rd</sup> digit and subchondral bone erosion as well as partial proximal interphalangeal joint collapse are seen.

**SEX COMPUTED TOMOGRAPHIC DIAGNOSIS**

Neutered Male

- Osteopathy and erosive arthropathy of the proximal phalanx and proximal interphalangeal joint in the 3<sup>rd</sup> digit with regional soft tissue swelling.

**AGE INTERPRETATION OF FINDINGS & FURTHER RECOMMENDATIONS**

3.5 Years

The CT findings strongly suggest periostitis and erosive arthritis of the proximal phalanx and proximal interphalangeal joint of the 3<sup>rd</sup> digit. Infectious periostitis and septic arthritis after local injury are thought by far most likely. Foreign material cannot be identified however poorly attenuating and hydrolyzed foreign material such as small pieces of organic foreign material cannot be ruled out entirely and traumatic noninfected periostitis and arthritis are thought less likely. There is no evidence of aggressive bone lesions at this time.

**INTERPRETED BY**

Nele Eley (Ondreka),  
DVM Dr. med. vet.,  
DipECVDI

**HOSPITAL NAME**

Mobile Pet Imaging

**REFERRING VET**

Meaux

**INVOICE**

52057

**DATE**

5-10-22



**PATIENT**

Duffy Kolmer

**SPECIES**

Canine

**BREED**

Gordon Setter

**SEX**

Neutered Male

**AGE**

3.5 Years

**INTERPRETED BY**

Nele Eley (Ondreka),  
DVM Dr. med. vet.,  
DipECVDI

**HOSPITAL NAME**

Mobile Pet Imaging

**REFERRING VET**

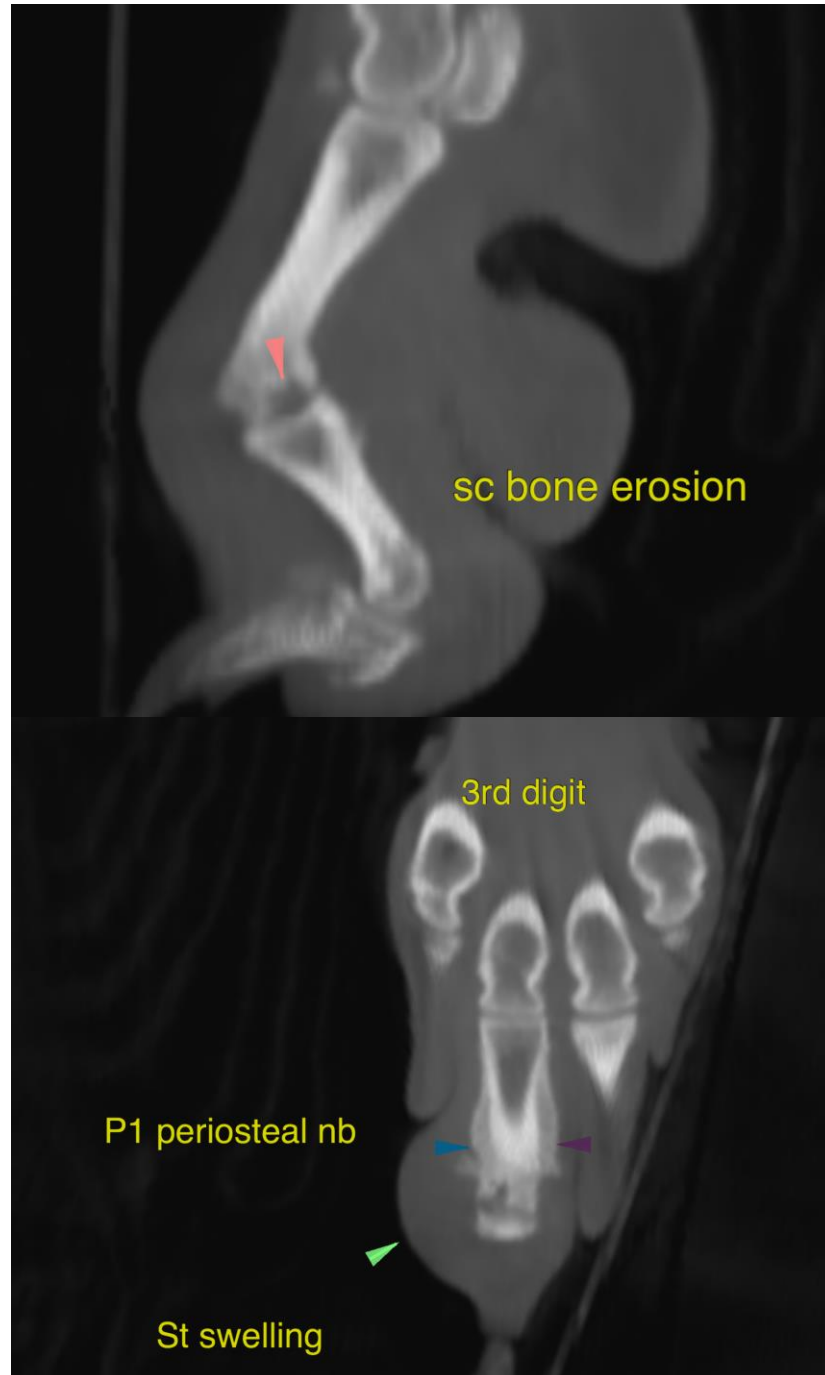
Meaux

**INVOICE**

52057

**DATE**

5-10-22



**PATIENT**

Duffy Kolmer

The information and recommendations provided are based on the images presented by the referring veterinarian. No evaluation can be communicated regarding pathology that was not visible in the image/video clips provided.

**SPECIES**

Canine

Thank you for this referral. If the clinical or image interpretation does not parallel your findings or if I can be of any further assistance please contact me.

**BREED**

Gordon Setter

**Nele Eley (Ondreka)**, DVM, Dr. med. vet., DipECVDI  
European Specialist in Veterinary Diagnostic Imaging, Cert. Radiology,  
Senior lecturer University of Giessen/Germany, Veterinary Faculty, Department of Radiology.  
Nele.Eley@sonopath.com

**SEX**

Neutered Male

**AGE**

3.5 Years

**INTERPRETED BY**

Nele Eley (Ondreka),  
DVM Dr. med. vet.,  
DipECVDI

**HOSPITAL NAME**

Mobile Pet Imaging

**REFERRING VET**

Meaux

**INVOICE**

52057

**DATE**

5-10-22