



## PATIENT

Gweg Pantos

## SPECIES

Canine

## BREED

Pocket Bully

## SEX

Male

## AGE

3

## WEIGHT

28

## INTERPRETED BY

Nele Eley (Ondreka),  
DVM Dr. med. vet.,  
DipECVDI

## IMAGING PERFORMED BY

Dr. Eamon

## HOSPITAL NAME

Belconnen Veterinary  
Centre

## REFERRING VET

Dr. Eamon

## INVOICE

74866

## DATE

5/1/26

## PRESENTING CLINICAL SIGNS

Pyrexia, neutropenia severe.

Abnormal PE/Chem/CBC/UA Results: Neutrophil count  $<0.3 \times 10^9$  urine pending blood smear pending bone marrow pending

## COMPUTED TOMOGRAPHIC STUDY OF THE THORAX & ABDOMEN

Plain and post-contrast studies in soft tissue, lung and bone windows available for review.

## COMPUTED TOMOGRAPHIC FINDINGS

### Thorax

Two well defined, rounded soft tissue structures are seen within the cranioventral mediastinum, each measuring approximately 2.0 cm in diameter. Widening of the cranial mediastinum is seen. These structures are mildly hypoenhancing relative to the surrounding soft tissues and are most consistent with enlarged cranial mediastinal lymph nodes. The remainder of the mediastinal lymph nodes, including the tracheobronchial lymph nodes, are mildly enlarged. The remaining mediastinum is unremarkable. Pulmonary parenchyma is normal with no nodules, masses, or infiltrates detected. No pleural effusion is present.

### Abdomen

The serosal fat presents normal attenuation behavior. There is no evidence of peritoneal effusion or peritonitis.

Both kidneys present within normal limits for size, shape and organ architecture. After contrast administration, a bilaterally symmetric and uniform nephro- and pyelogram is noted.

The adrenal glands are within normal limits for size, shape and organ architecture.

Both the liver and the spleen present with normal shape, even surface, uniformly attenuating parenchyma, and homogeneous contrast enhancement.

The pancreas is evenly contoured. The pancreatic parenchyma is homogeneous and presents uniform contrast enhancement.

The position, delineation, wall, and content of the gastrointestinal tract are considered within normal limits throughout.

Mild generalized enlargement of abdominal lymph nodes is noted.

Both coxofemoral joints present severe signs of dysplasia with moderate secondary osteoarthritis.

## COMPUTED TOMOGRAPHIC DIAGNOSIS

- Cranioventral mediastinal masses, likely lymph nodes, with mild generalized lymphadenomegaly.
- No pulmonary or abdominal parenchymal abnormalities identified.
- Severe bilateral hip dysplasia with moderate osteoarthritis unrelated to reason for presentation.



## PATIENT

Gweg Pantos

## SPECIES

Canine

## BREED

Pocket Bully

## SEX

Male

## AGE

3

## WEIGHT

28

## INTERPRETED BY

Nele Eley (Ondreka),  
DVM Dr. med. vet.,  
DipECVDI

## IMAGING PERFORMED BY

Dr. Eamon

## HOSPITAL NAME

Belconnen Veterinary  
Centre

## REFERRING VET

Dr. Eamon

## INVOICE

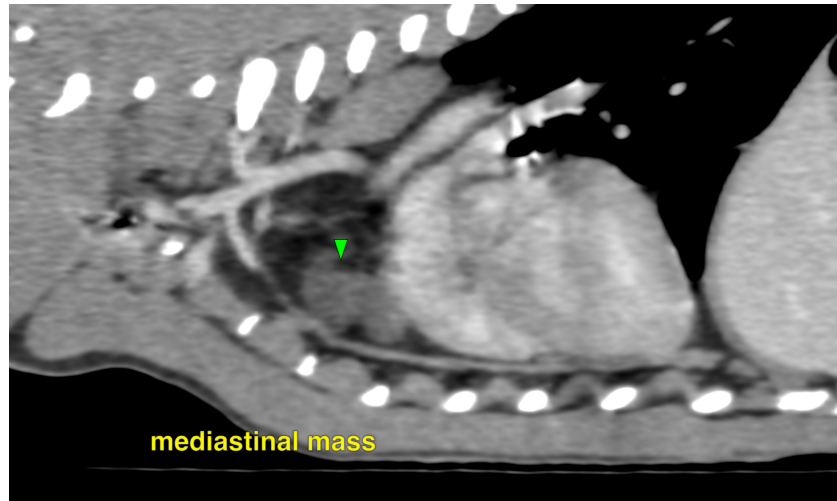
74866

## DATE

5/1/26

## INTERPRETATION OF FINDINGS & FURTHER RECOMMENDATIONS

The presence of cranial mediastinal lymph node enlargement combined with mild generalized lymphadenopathy in a young dog with fever and severe neutropenia raises concern for systemic disease such as lymphoma, severe systemic infection, immune mediated or inflammatory disease. Fine needle aspirate or biopsy of enlarged lymph nodes such as in the cranial mediastinum under ultrasonographic guidance is recommended if not already performed. Bone marrow evaluation is pending. Correlation with blood smear and infectious disease testing is recommended as well.



The information and recommendations provided are based on the images presented by the referring veterinarian. No evaluation can be communicated regarding pathology that was not visible in the image/video clips provided.

Thank you for this referral. If the clinical or image interpretation does not parallel your findings or if I can be of any further assistance please contact me.

**Nele Eley (Ondreka)**, DVM, Dr. med. vet., DipECVDI  
European Specialist in Veterinary Diagnostic Imaging, Cert. Radiology,  
Senior lecturer University of Giessen/Germany, Veterinary Faculty, Department of Radiology.  
[info@sonopath.com](mailto:info@sonopath.com)