

**PATIENT PRESENTING CLINICAL SIGNS**

Phenom Xavier 6yo MN Bernese Mountain Dog presented for evaluation of difficulty standing from a sitting position and generalized/non-specific pain. On physical exam, patient is BAR, no lameness noted, and normothermic.

SPECIES

Canine

COMPUTED TOMOGRAPHIC STUDY OF THE THORACIC & LUMBAR SPINE

Plain and post contrast studies of the thoracolumbar spine and repeat study of the lumbosacral junction in extended position available for review.

BREEDBernese Mountain
Dog**COMPUTED TOMOGRAPHIC FINDINGS**

Number, alignment, and general anatomy of the thoracic and lumbar vertebrae present within normal limits.

SEX

MN

Moderate spondylosis deformans with mild intervertebral disc space narrowing and mild intervertebral disc protrusion are seen between L2 and L3 within the lumbar spine.

AGE

6 Years

The lumbosacral intervertebral disc presents moderate protrusion as well as a mild vacuum phenomenon of the in situ intervertebral disc material. The degree of lumbosacral disc protrusion is reduced in extended position of the lumbosacral junction.

Mild narrowing of the sacrocaudal intervertebral disc space with mild smooth new bone formation is seen.

INTERPRETED BYNele Eley (Ondreka),
DVM Dr. med. vet.,
DipECVDI**COMPUTED TOMOGRAPHIC DIAGNOSIS**

- Moderate degenerative lumbosacral stenosis
- Mild chronic L2/3 intervertebral disc protrusion with spondylosis deformans.

INTERPRETATION OF FINDINGS & FURTHER RECOMMENDATIONS**HOSPITAL NAME**

Mobile Pet Imaging

The CT study reveals moderate degenerative lumbosacral stenosis. The vacuum phenomenon supports the presence of progressive degenerative intervertebral disc disease. Moderate protrusion of the annulus fibrosus is noted and stationary or intermittent cauda equina compression is a potential.

REFERRING VET

Seraydar

The L2/3 intervertebral disc protrusion is mild, however, may contribute to the clinical pain.

INVOICE

58054

DATE

5-1-23



PATIENT

Phenom Xavier

SPECIES

Canine

BREED

Bernese Mountain
Dog

SEX

MN

AGE

6 Years

INTERPRETED BY

Nele Eley (Ondreka),
DVM Dr. med. vet.,
DipECVDI

HOSPITAL NAME

Mobile Pet Imaging

REFERRING VET

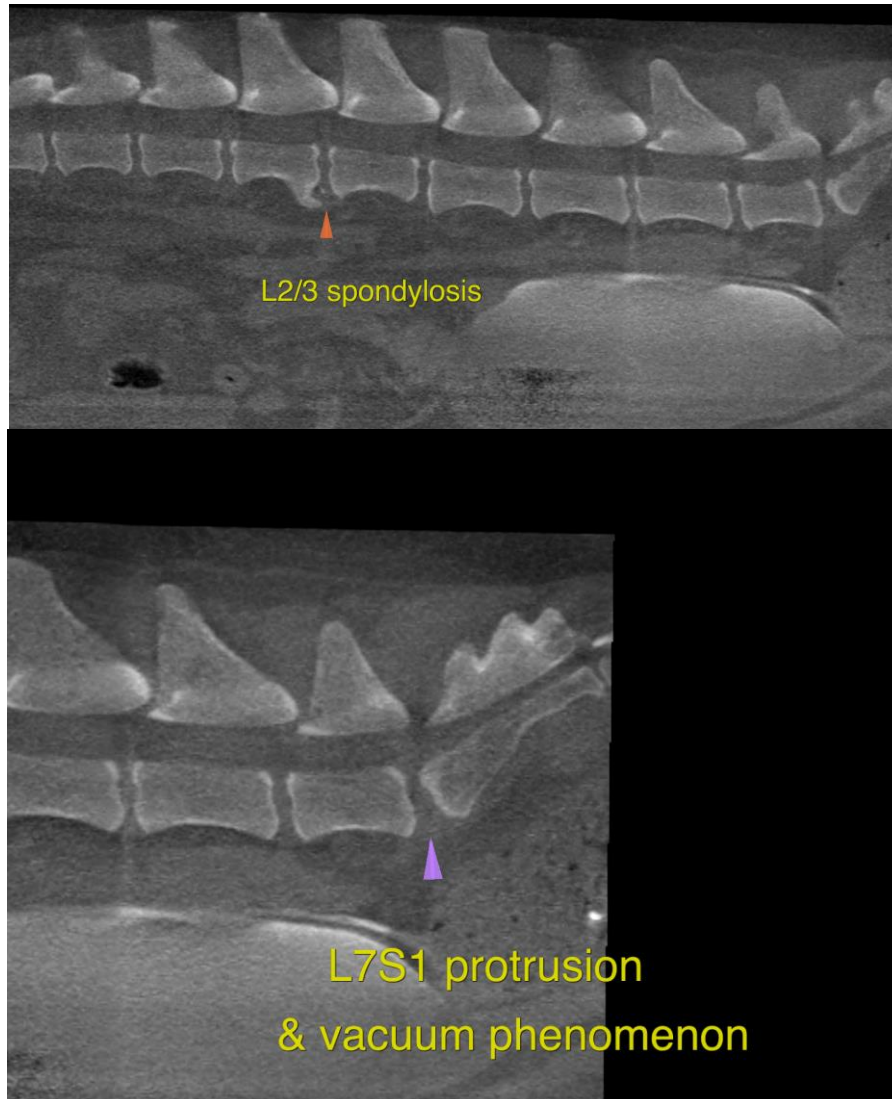
Seraydar

INVOICE

58054

DATE

5-1-23



The information and recommendations provided are based on the images presented by the referring veterinarian. No evaluation can be communicated regarding pathology that was not visible in the image/video clips provided.

Thank you for this referral. If the clinical or image interpretation does not parallel your findings or if I can be of any further assistance please contact me.

Nele Eley (Ondreka), DVM, Dr. med. vet., DipECVDI
European Specialist in Veterinary Diagnostic Imaging, Cert. Radiology,
Senior lecturer University of Giessen/Germany, Veterinary Faculty, Department of Radiology.
Nele.Eley@sonopath.com