



PATIENT

Max Catapano

PRESENTING CLINICAL SIGNS

History of right THR when young.(Consult with owner's father unsure when surgery was done) PWBL RHL Positive cranial drawer instability right stifle. Slight decrease extension on right hip joint Sedated radiographs performed: 1) Hips - Severe loss of extension of both CF joint - unable to get normal VD positioning

SPECIES

Canine

RADIOGRAPHIC STUDY OF THE PELVIS & STIFLES

Mediolateral and craniocaudal views of the right stifle joint, ventrodorsal flexed views of the hip, and lateral flexed views of the pelvis totaling 6 images available for review.

BREED

Golden Retriever

RADIOGRAPHIC FINDINGS

Right Stifle

Moderate articular swelling of the right stifle joint as well as moderate cranial thrust of the tibia with respect to the femoral condyles are seen.

SEX

MN

There is a moderate amount of periarticular osteophytes accentuating the femoral patella joint, fabellae, and popliteal sesamoid bones.

AGE

7 Years

Reduced muscle volume of the right hind limb is seen.

Pelvis

Patient has a history of total hip replacement of the right hind limb.

The implant appears to be in situ and intact. A mild radiolucent halo is seen in the neck of the shaft of the femoral implant.

Increased medullary opacity with cloudy appearance is seen throughout the diaphysis of the right femur which is due to the cemented hip implantation.

Severe dysplasia and coxofemoral joint osteoarthritis of the left hip joint are noted with reduced opacity suggesting chronic disuse in the femoral head and neck.

INTERPRETED BY

Nele Eley, DVM
Dr. med. Vet. DipECVDI

HOSPITAL NAME

Animal Surgical
Center

REFERRING VET

Meadowbrook AH

The patient's body condition score is excessive.

Severe bridging spondyloses are seen within the caudal lumbar spine as well as at the lumbosacral junction.

INVOICE

58059

- History of total hip replacement with a cemented system in the right hind limb.
- Radiographic evidence of cruciate ligament injury and moderate stifle osteoarthritis in the right rear limb and disuse atrophy of the right rear limb musculature.

DATE

5-1-23

- Severe coxofemoral joint dysplasia and osteoarthritis in the left rear limb.
- Multiple lumbar spondyloses
- Degenerative lumbosacral stenosis.



PATIENT

Max Catapano

INTERPRETATION OF THE FINDINGS & FURTHER RECOMMENDATIONS

The findings of the right coxofemoral joint are within expected limits after long term total hip replacement. No obvious radiographic signs of complication are identified.

SPECIES

Canine

The findings of the right stifle joint are compatible with cruciate ligament pathology with biomechanical failure of the ligament's function and cranial thrust of the tibia as well as concurrent moderate osteoarthritic changes.

BREED

Golden Retriever

Chronic disuse of the right rear limb is indicated by the loss of its muscle volume.

The left coxofemoral joint presents signs of severe dysplasia with severe secondary osteoarthritis.

Weight management appears to be an issue in this patient.

SEX

MN

AGE

7 Years

INTERPRETED BY

Nele Eley, DVM
Dr. med. Vet. DipECVDI

HOSPITAL NAME

Animal Surgical
Center

REFERRING VET

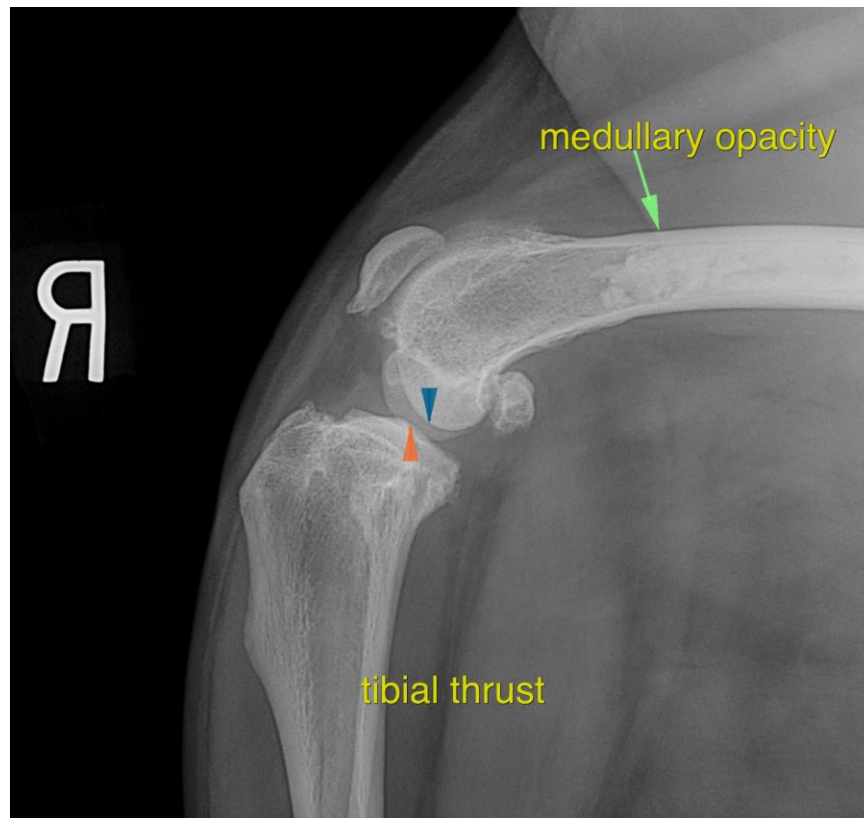
Meadowbrook AH

INVOICE

58059

DATE

5-1-23





PATIENT

Max Catapano

The information and recommendations provided are based on the images presented by the referring veterinarian/sonographer. No evaluation can be communicated regarding pathology that was not visible in the image/video clips provided.

SPECIES

Canine

Thank you for this referral. If the clinical or image interpretation does not parallel your findings or if I can be of any further assistance please contact me.

BREED

Golden Retriever

Nele Eley, DVM, Dr. med. vet., DipECVDI
European Specialist in Veterinary Diagnostic Imaging, Cert. Radiology,
Senior lecturer University of Giessen, Germany, Veterinary Faculty, Department of Radiology
Nele.Eley@sonopath.com

SEX

MN

AGE

7 Years

INTERPRETED BY

Nele Eley, DVM
Dr. med. Vet. DipECVDI

HOSPITAL NAME

Animal Surgical
Center

REFERRING VET

Meadowbrook AH

INVOICE

58059

DATE

5-1-23