



PATIENT

Oreo Hubert

PRESENTING CLINICAL SIGNS

Patient presented for stiff gait and leaning more towards left side as well as having muscle spasms, uncomfortable on abdominal palpation (possibly due to liver) Panting a lot at home, no obvious murmur but difficult to auscultate

SPECIES

Canine

RADIOGRAPHIC STUDY OF THE THORAX & ABDOMEN

Right/left lateral and ventrodorsal whole body views totaling 3 images available for review.

BREED

Pomeranian

RADIOGRAPHIC FINDINGS

Thorax

Moderate bilateral shoulder osteoarthritis is noted.

SEX

FS

The thoracic volume is small.

The degree of pulmonary inflation is fair.

AGE

9 Years

A moderate generalized bronchial lung pattern with mild peribronchial cuffing is seen.

There is moderate left sided cardiomegaly with a vertebral heart score of 11.6. The trachea is elevated towards the thoracic spine. Left atrial tenting is noted. At this time there is no evidence of cardiogenic pulmonary edema.

INTERPRETED BY

Nele Eley, DVM
Dr. med. Vet. DipECVDI

The width of the trachea is within normal limits on the lateral views.

Abdomen

The patient is obese.

HOSPITAL NAME

Boca Park Animal
Hospital

The abdominal volume is large.

The ventral abdominal wall appears to be pendulous.

Moderate generalized enlargement of the liver is seen.

REFERRING VET

Dr. Corinna Gorgon

Crowding of the bowel is noted in the mid and caudal abdomen with a large amount of inspissated fecal material within the colon. The diameter of the colon appears to be widened in general.

Severe bilateral coxofemoral joint dysplasia and osteoarthritis is seen.

INVOICE

51436

One stifle joint is projected and presents moderate osteoarthritic changes.

Chronic intervertebral disc disease within the cranial lumbar spine is seen at L1/2.

DATE

4-9-22

RADIOGRAPHIC DIAGNOSIS

- Moderate generalized hepatomegaly.
- Constipation and dilation of the colon.



PATIENT

Oreo Hubert

- Moderate left sided cardiomegaly with no radiographic evidence of congestive heart failure.
- Shoulders, stifle, and coxofemoral joint osteoarthritis.
- Chronic intervertebral disc disease within the cranial lumbar spine at L1/2.

INTERPRETATION OF THE FINDINGS & FURTHER RECOMMENDATIONS

SPECIES

Canine

Differential diagnosis for the hepatomegaly includes endocrine/metabolic hepatopathy. A diffuse inflammatory or neoplastic infiltrate cannot be ruled out entirely. Correlate with the laboratory values and consider ultrasound as well as parenchymal sampling for further definition if indicated.

BREED

Pomeranian

The colon appears to be constipated and dilated which may represent uncomplicated constipation. Primary or secondary megacolon cannot be ruled out entirely. The presence of perineal hernia or other perianal / perineal disease should be ruled out.

SEX

FS

The abdominal serosal detail is mildly reduced in the mid abdomen which is thought to be a consequence of the intestinal crowding rather than representing peritoneal fluid.

AGE

9 Years

Note the presence of moderate left sided cardiomegaly with left atrial enlargement. Myxomatous degeneration of the mitral valve with chronic mitral valve regurgitation is considered likely. At this time there is no evidence of cardiogenic pulmonary edema. Consider a full cardiac echo for detailed staging.

INTERPRETED BY

Nele Eley, DVM
Dr. med. Vet. DipECVDI

HOSPITAL NAME

Boca Park Animal
Hospital

REFERRING VET

Dr. Corinna Gorgon

INVOICE

51436

DATE

4-9-22



PATIENT

Oreo Hubert

SPECIES

Canine

BREED

Pomeranian

SEX

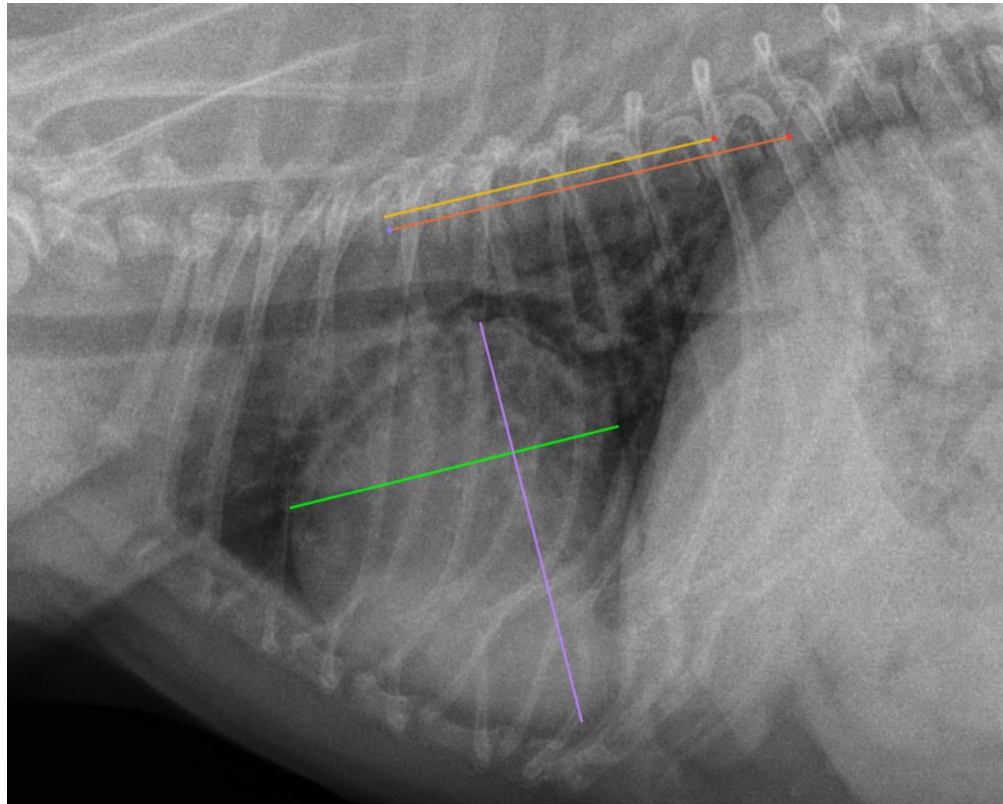
FS

AGE

9 Years

INTERPRETED BY

Nele Eley, DVM
Dr. med. Vet. DipECVDI



HOSPITAL NAME

Boca Park Animal
Hospital

REFERRING VET

Dr. Corinna Gorgon

INVOICE

51436

DATE

4-9-22

The information and recommendations provided are based on the images presented by the referring veterinarian/sonographer. No evaluation can be communicated regarding pathology that was not visible in the image/video clips provided.

Thank you for this referral. If the clinical or image interpretation does not parallel your findings or if I can be of any further assistance please contact me.

Nele Eley, DVM, Dr. med. vet., DipECVDI
European Specialist in Veterinary Diagnostic Imaging, Cert. Radiology,
Senior lecturer University of Giessen, Germany, Veterinary Faculty, Department of Radiology
Nele.Eley@sonopath.com