



PATIENT

Milton Hsu

PRESENTING CLINICAL SIGNS

Patient presents as a transfer from rDVM due to acute onset paraplegia that started the day prior. Vertebral column survey radiographs display disc calcification at T11-T12 from rDVM. Paraplegia, absent proprioception bilaterally in the pelvic limbs, deep pain sensation absent bilaterally in the pelvic limbs and tail (tested with hemostatic forceps), panniculus reflex absent caudal to T-L junction, painful on T-L spinal palpation and decreased spinal reflexes. Multiple areas of dark discoloration were observed along the spinal cord under the dura mater intra-op. Owners informed regarding guarded prognosis for mobility given intra-op findings.

SPECIES

Canine

BREED

Dachshund

COMPUTED TOMOGRAPHIC STUDY OF THE THORACOLUMBAR SPINE

Plain and post IV contrast studies available for review. The study is right/left flipped.

COMPUTED TOMOGRAPHIC FINDINGS

SEX

MN

Moderate intervertebral disc space narrowing is noted in the caudal thoracic spine between T12 and T13. There is a moderate heterogeneously hyperattenuating extrusion of intervertebral disc material emerging from the T12/13 intervertebral disc. The extruded disc material presents predominance of cranial and only mild caudal migration. Most of the material is situated in the left ventral epidural space level with the 12th thoracic vertebra and extends throughout the entire length of T12. Approximately 30% of the vertebral canal's cross sectional area is occupied by the extruded material. Moderate rightward and dorsal deviation and compression of the spinal cord is seen.

AGE

5 Years, 5 Months

INTERPRETED BY

Nele Eley, DVM
Dr. med. Vet. DipECVDI

Multiple other intervertebral discs reveal evidence of chondroid disc degeneration.

COMPUTED TOMOGRAPHIC DIAGNOSIS

- Acute moderately compressive left sided intervertebral disc extrusion between T12 and T13 with extensive cranial migration.
- Multiple chondroid disc degeneration.

HOSPITAL NAME

South Bay Animal Hospital

INTERPRETATION OF THE FINDINGS & FURTHER RECOMMENDATIONS

The CT study reveals T12/13 intervertebral disc extrusion with moderate spinal cord compression. Most of the material is situated in the left ventral epidural space (study is right/left flipped) and causes moderate dorsal and rightward deviation and compression of the spinal cord. The heterogeneity of the material may represent intervertebral disc material mixed with hemorrhage from the ventral vertebral venous plexus. The extrusion presents extensive cranial migration.

REFERRING VET

Ravinder Atwal, DVM, CCRP

INVOICE

51376

DATE

4-8-22



PATIENT

Milton Hsu

SPECIES

Canine

BREED

Dachshund

SEX

MN

AGE

5 Years, 5 Months

INTERPRETED BY

Nele Eley, DVM
Dr. med. Vet. DipECVDI

HOSPITAL NAME

South Bay Animal
Hospital

REFERRING VET

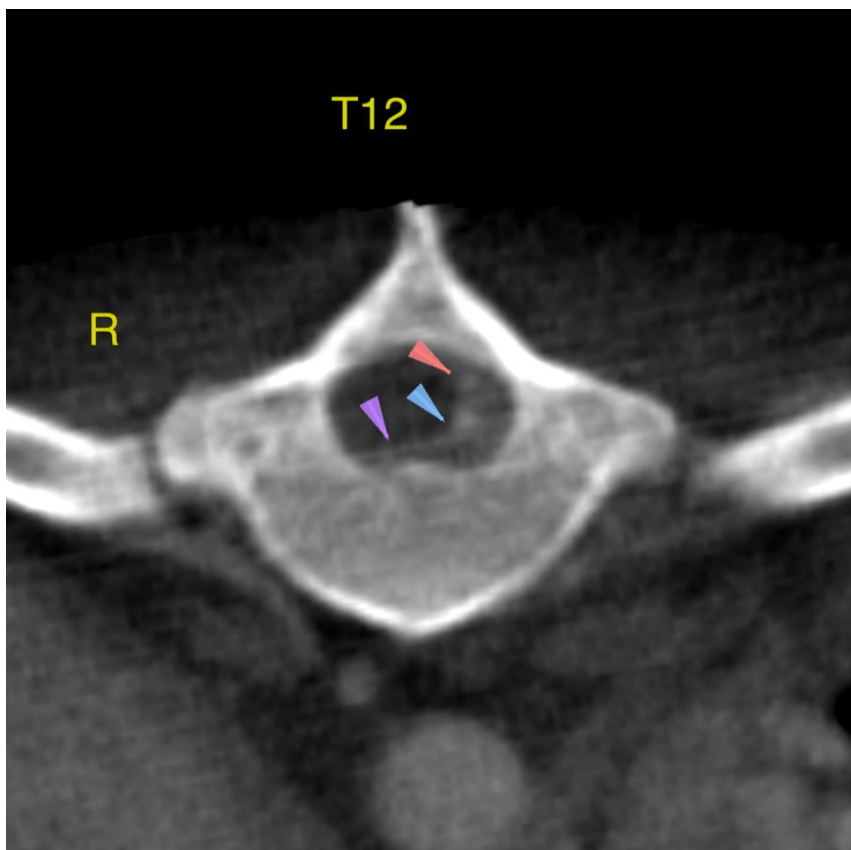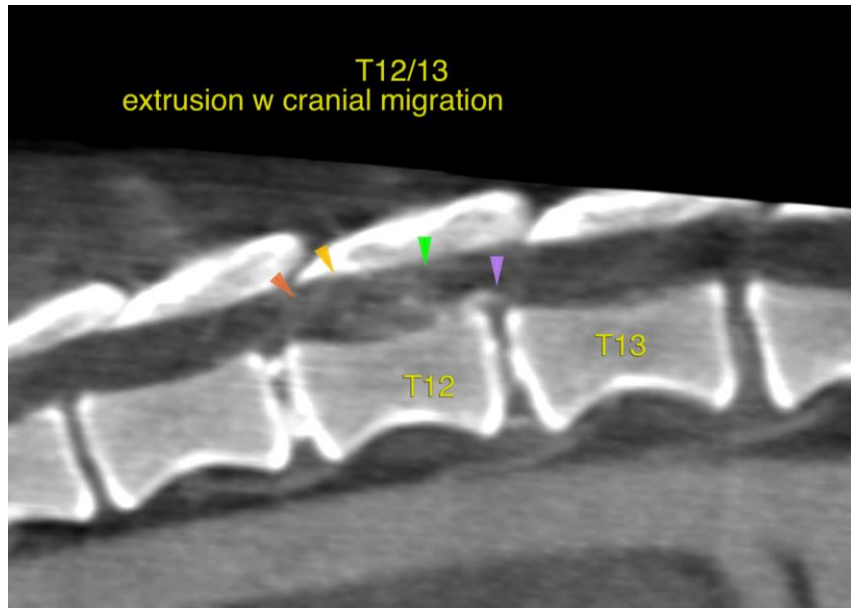
Ravinder Atwal, DVM,
CCRP

INVOICE

51376

DATE

4-8-22





PATIENT

Milton Hsu

The information and recommendations provided are based on the images presented by the referring veterinarian/sonographer. No evaluation can be communicated regarding pathology that was not visible in the image/video clips provided.

SPECIES

Canine

Thank you for this referral. If the clinical or image interpretation does not parallel your findings or if I can be of any further assistance please contact me.

BREED

Dachshund

Nele Eley, DVM, Dr. med. vet., DipECVDI
European Specialist in Veterinary Diagnostic Imaging, Cert. Radiology,
Senior lecturer University of Giessen, Germany, Veterinary Faculty, Department of Radiology
Nele.Eley@sonopath.com

SEX

MN

AGE

5 Years, 5 Months

INTERPRETED BY

Nele Eley, DVM
Dr. med. Vet. DipECVDI

HOSPITAL NAME

South Bay Animal
Hospital

REFERRING VET

Ravinder Atwal, DVM,
CCRP

INVOICE

51376

DATE

4-8-22