



**PATIENT**

Chloe Thorpe

**PRESENTING CLINICAL SIGNS**

Weight loss over 6 months, Vomiting, decreased appetite

**RADIOGRAPHIC STUDY OF THE THORAX & ABDOMEN**

**SPECIES**

Canine

Left lateral and ventrodorsal view of the thorax and right/left lateral and ventrodorsal views of the abdomen totaling 6 images available for review.

**RADIOGRAPHIC FINDINGS**

**BREED**

Golden Ret

**Thorax**

The cardiac silhouette is upright and thin. The pulmonary vasculature and caudal vena cava are thin.

**SEX**

Female/S

The lung and bronchial tree are considered within age related normal limits. Incidental pulmonary osteomas are seen.

Course and width of the trachea are considered within normal limits.

**AGE**

11 Years

There is no evidence of abnormal mediastinal widening.

The thoracic boundaries present within normal limits.

**INTERPRETED BY**

Nele Eley, DVM  
Dr. med. Vet. DipECVDI

**Abdomen**

The abdominal serosal detail is maintained.

The stomach contains food and a moderate amount of fluid within the gastric pylorus. A mild amount of mineral opaque material is seen in the gastric pylorus as well.

**HOSPITAL NAME**

Pacific Avenue  
Veterinary Clinic

There is one dilated bowel loop with a discrepant gas pattern seen in the mid abdomen on the left lateral view of the abdomen. The remainder of the small bowel presents nondilated.

The colon contains a mild amount of fecal material.

**REFERRING VET**

Dr. Sid Bruckert-Frisk

The kidneys, liver, and urinary bladder present within the expected limits.

**RADIOGRAPHIC DIAGNOSIS**

- Suspect chronic subileus owing to gastric gravel sign and probable sentinel bowel loop.
- Hypovolemia with microcardia and underperfusion of the lung.

**INVOICE**

51425

**INTERPRETATION OF THE FINDINGS & FURTHER RECOMMENDATIONS**

**DATE**

4-8-22

The radiographic findings of the abdomen suggest potential for partial mechanical ileus. The gravel sign supports the presence of partial outflow obstruction of the gastric outlet with filtration of solid ingesta. Moreover, the mildly dilated bowel loop with discrepant gas pattern may represent small bowel. Structural GI tract pathology with a subileus is considered a potential based on the radiographic findings and patient history. Further definition by means of abdominal ultrasound is strongly recommended if not performed already.



**PATIENT**

Chloe Thorpe

**SPECIES**

Canine

**BREED**

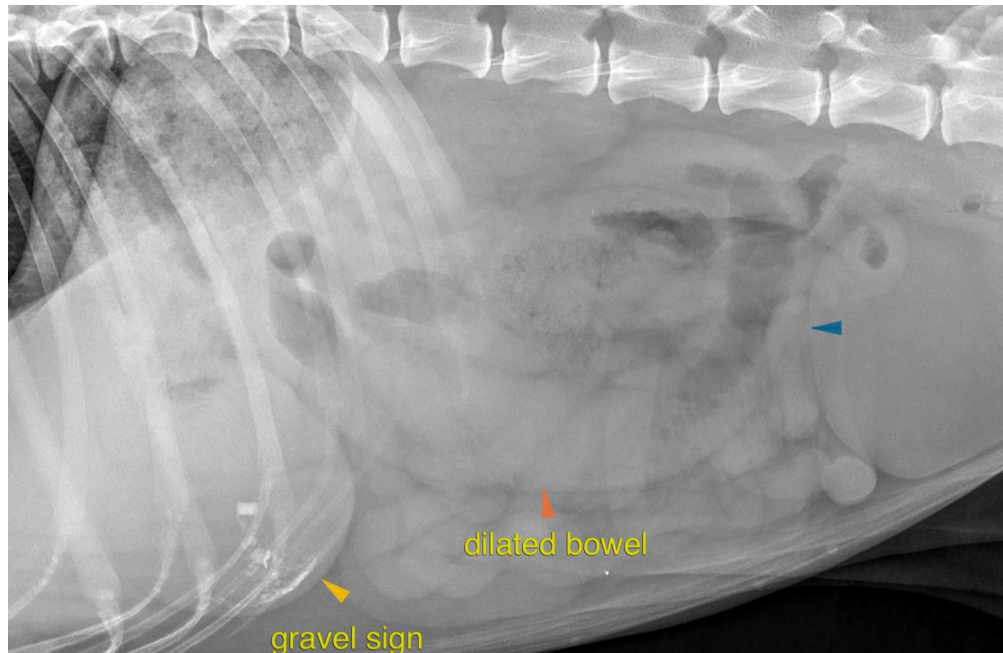
Golden Ret

**SEX**

Female/S

**AGE**

11 Years



**INTERPRETED BY**

Nele Eley, DVM  
Dr. med. Vet. DipECVDI

The information and recommendations provided are based on the images presented by the referring veterinarian/sonographer. No evaluation can be communicated regarding pathology that was not visible in the image/video clips provided.

**HOSPITAL NAME**

Pacific Avenue  
Veterinary Clinic

Thank you for this referral. If the clinical or image interpretation does not parallel your findings or if I can be of any further assistance please contact me.

**Nele Eley**, DVM, Dr. med. vet., DipECVDI  
European Specialist in Veterinary Diagnostic Imaging, Cert. Radiology,  
Senior lecturer University of Giessen, Germany, Veterinary Faculty, Department of Radiology  
Nele.Eley@sonopath.com

**REFERRING VET**

Dr. Sid Bruckert-Frisk

**INVOICE**

51425

**DATE**

4-8-22