

**PATIENT**

Bubbles Gasbarra

PRESENTING CLINICAL SIGNS

Patient was hit by car a few months ago, has recovered well. Patient did have some teeth fall out, no other apparent issues at this time.

SPECIES

Canine

COMPUTED TOMOGRAPHIC STUDY OF THE DENTAL ARCADES

Plain study available for review.

BREEDAustralian Shepherd
Mix**COMPUTED TOMOGRAPHIC FINDINGS**

Patient has a history of traumatic injury of the facial bones.

The dentition is incomplete. The triadans 101-103 and 401-403 are absent.

The remnants of the triadan 104 present comminuted complicated fracture with open pulpal cavum. Only fragments of the tooth root are maintained with gas inclusion and moderate irregular widening of the periodontium.

SEX

Female Spayed

Mild deformity of the maxillae and mandibles is seen with rightward deviation of the tip of the nose and mild leftward deviation of the bony nasal septum in the mid third of the nasal cavities. However, the overall maxillomandibular occlusion appears to be within satisfying limits. No maxillomandibular fracture and no temporomandibular joint fracture or luxation are seen.

AGE

9 Months

COMPUTED TOMOGRAPHIC DIAGNOSIS**INTERPRETED BY**Nele Eley, DVM
Dr. med. Vet. DipECVDI

- Chronic complicated and comminuted fracture of the triadan 104 with pulpitis and alveolitis.
- Incomplete dentition with absent tooth elements 101-103 and 401-403.
- Mild angular deformity of the maxillary bones, nasal bones, and mandibles with overall good occlusion.

HOSPITAL NAMEScottsdale Veterinary
Clinic**INTERPRETATION OF THE FINDINGS & FURTHER RECOMMENDATIONS**

The chronic traumatic osseous and dental injury appears to have resulted in the loss of the tooth elements 101-103 and 401-403 with mild rightward deviation of the tip of the nose. The maxillomandibular occlusion appears to be within satisfying limits at this time.

REFERRING VET

Dr. Magnussen

Note the presence of comminuted and complicated fracture of the triadan 104 with remnants of the fragmented tooth root within its dental alveolus and signs of pulpitis as well as alveolitis. Removal of the tooth fragments should be considered.

INVOICE

51426

DATE

4-8-22



PATIENT

Bubbles Gasbarra

SPECIES

Canine

BREED

Australian Shepherd
Mix

SEX

Female Spayed

AGE

9 Months

INTERPRETED BY

Nele Eley, DVM
Dr. med. Vet. DipECVDI

HOSPITAL NAME

Scottsdale Veterinary
Clinic

REFERRING VET

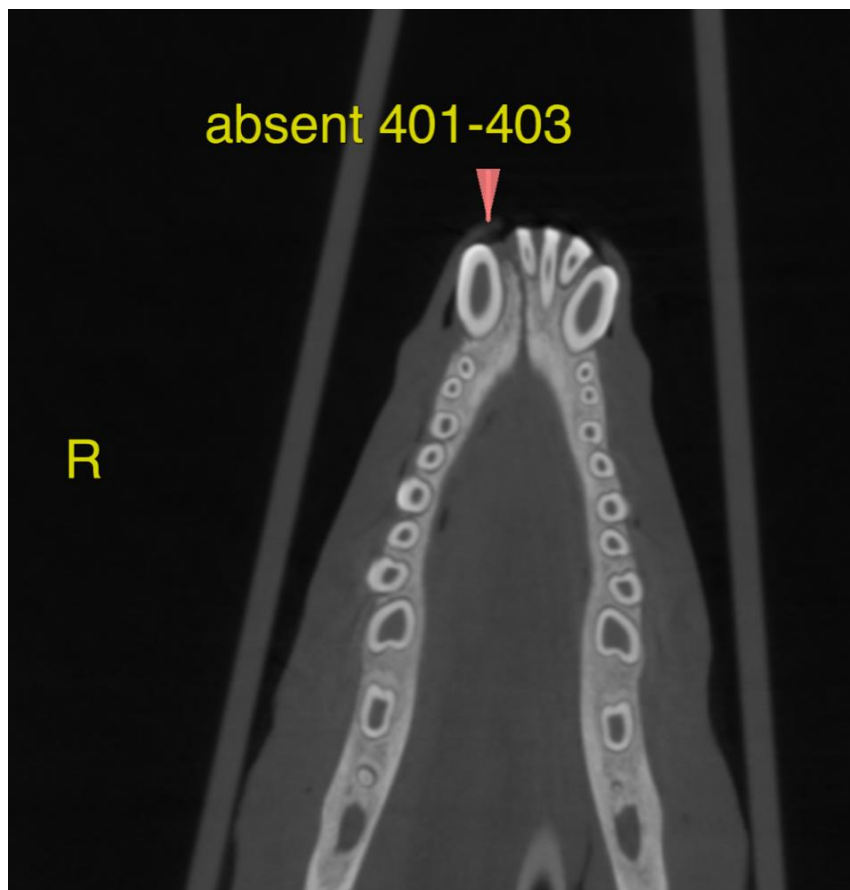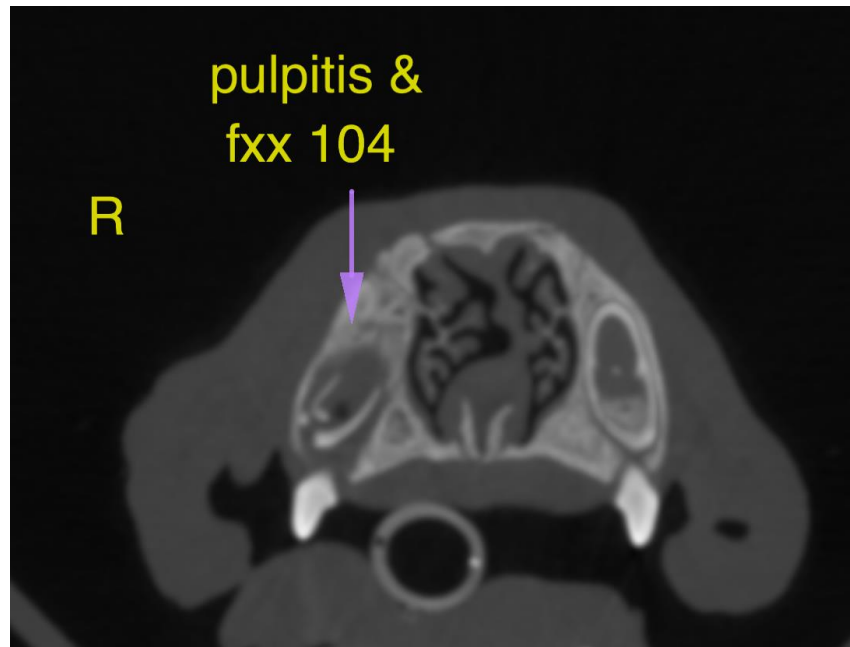
Dr. Magnussen

INVOICE

51426

DATE

4-8-22





PATIENT

Bubbles Gasbarra

SPECIES

Canine

BREED

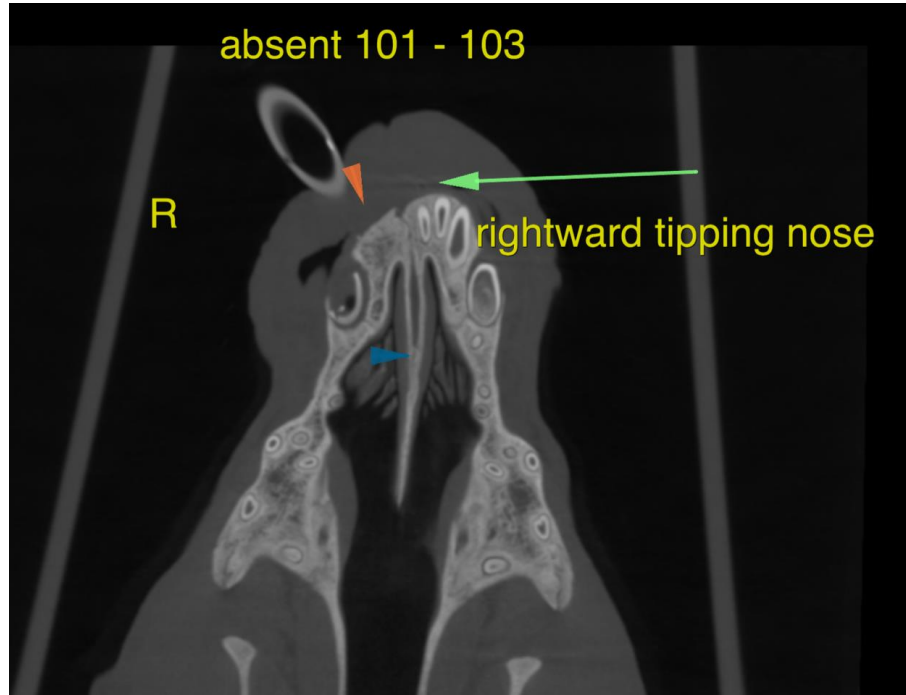
Australian Shepherd
Mix

SEX

Female Spayed

AGE

9 Months



INTERPRETED BY

Nele Eley, DVM
Dr. med. Vet. DipECVDI

The information and recommendations provided are based on the images presented by the referring veterinarian/sonographer. No evaluation can be communicated regarding pathology that was not visible in the image/video clips provided.

Thank you for this referral. If the clinical or image interpretation does not parallel your findings or if I can be of any further assistance please contact me.

HOSPITAL NAME

Scottsdale Veterinary
Clinic

Nele Eley, DVM, Dr. med. vet., DipECVDI
European Specialist in Veterinary Diagnostic Imaging, Cert. Radiology,
Senior lecturer University of Giessen, Germany, Veterinary Faculty, Department of Radiology
Nele.Eley@sonopath.com

REFERRING VET

Dr. Magnussen

INVOICE

51426

DATE

4-8-22