



PATIENT

Jax Abend

SPECIES

K9

BREED

German Shep Dog

SEX

MN

AGE

11Y

WEIGHT

53kg

INTERPRETED BY

Nele Eley (Ondreka),
DVM Dr. med. vet.,
DipECVDI

IMAGING PERFORMED BY

James Gaynor

HOSPITAL NAME

Buffalo Mountain
Animal Hospital

REFERRING VET

James Gaynor

INVOICE

74505

DATE

4-7-26

PRESENTING CLINICAL SIGNS

- Multi month history of rear limb lameness +/- ataxia

Abnormal PE/Chem/CBC/UA Results: EXAM: Right hip pain : OA Bilateral knee extension pain + mild laxity Rad: Bilateral knee effusion

ULTRASONOGRAPHIC FINDINGS

Right Stifle

Moderate anechoic effusion is present within the supra- and infra-patellar recesses of the right stifle joint. The cranial cruciate ligament shows disruption of echogenic fibers with a surrounding hypoechoic halo compatible with fiber tearing and inflammation. No abnormalities are identified in the visible portions of the medial meniscus.

Left Stifle

Moderate anechoic effusion is present within the supra- and infra-patellar recesses of the left stifle joint. The cranial cruciate ligament shows disruption of echogenic fibers with a surrounding hypoechoic halo compatible with fiber tearing and inflammation. No abnormalities are identified in the visible portions of the medial meniscus.

ULTRASONOGRAPHIC DIAGNOSIS

Right Stifle

- Findings consistent with CCL rupture, likely complete with associated joint effusion and osteoarthritis.

Left Stifle

- Findings consistent with partial CCL tear with mild osteoarthritis and effusion.
- No ultrasonographic evidence of medial meniscal tear in the visualized portions.

INTERPRETATION OF FINDINGS & FURTHER RECOMMENDATIONS

The right stifle shows changes typical of a functionally unstable joint due to CCL rupture. The left stifle demonstrates partial CCL tear. Consider orthopedic stabilization of the right stifle. Surgical options such as TPLO or TTA should be considered. Left stifle monitoring is advised with surgical intervention depending on clinical progression.



PATIENT

Jax Abend

SPECIES

K9

BREED

German Shep Dog

SEX

MN

AGE

11Y

WEIGHT

53kg

INTERPRETED BY

Nele Eley (Ondreka),
DVM Dr. med. vet.,
DipECVDI

IMAGING PERFORMED BY

James Gaynor

HOSPITAL NAME

Buffalo Mountain
Animal Hospital

REFERRING VET

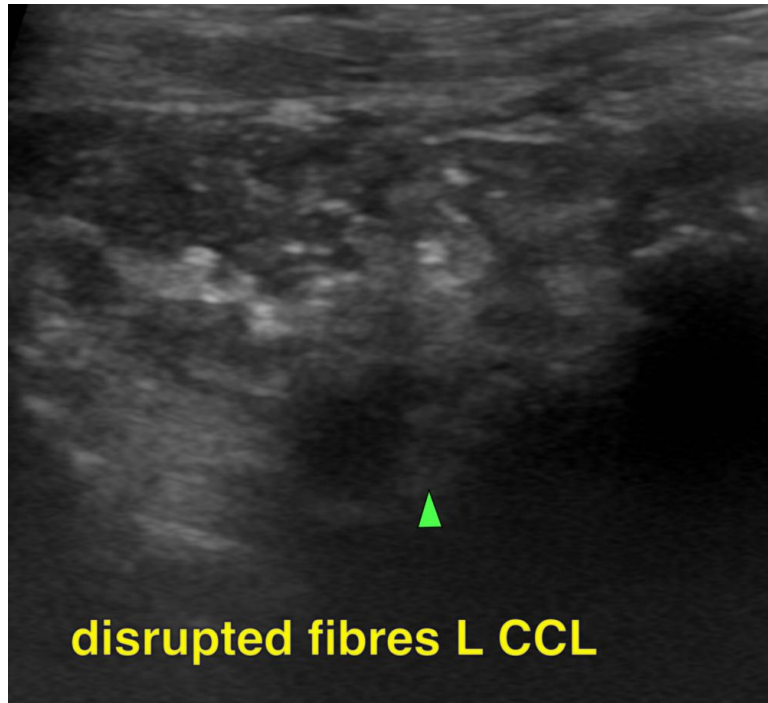
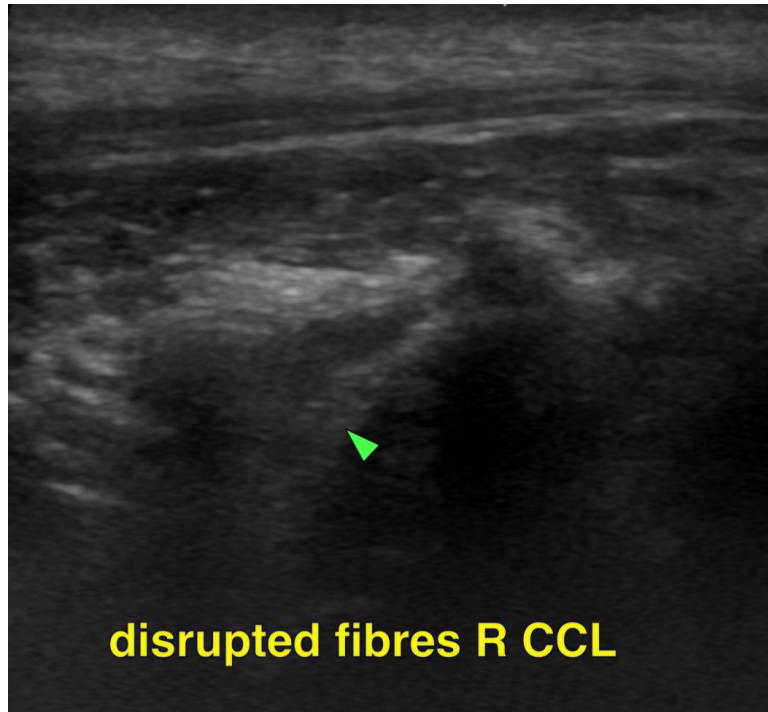
James Gaynor

INVOICE

74505

DATE

4-7-26





PATIENT

Jax Abend

SPECIES

K9

BREED

German Shep Dog

SEX

MN

AGE

11Y

WEIGHT

53kg

INTERPRETED BY

Nele Eley (Ondreka),
DVM Dr. med. vet.,
DipECVDI

IMAGING PERFORMED BY

James Gaynor

HOSPITAL NAME

Buffalo Mountain
Animal Hospital

REFERRING VET

James Gaynor

INVOICE

74505

DATE

4-7-26

The information and recommendations provided are based on the images presented by the referring veterinarian. No evaluation can be communicated regarding pathology that was not visible in the image/video clips provided.

Thank you for this referral. If the clinical or image interpretation does not parallel your findings or if I can be of any further assistance please contact me.

Nele Eley (Ondreka), DVM, Dr. med. vet., DipECVDI

European Specialist in Veterinary Diagnostic Imaging, Cert. Radiology,

Senior lecturer University of Giessen/Germany, Veterinary Faculty, Department of Radiology.

info@sonopath.com