



**PATIENT PRESENTING CLINICAL SIGNS**

**PATIENT**  
Cujo Julian

**SPECIES**  
Feline

**BREED**  
DHS

**SEX**  
MN

**AGE**  
13 Years

**INTERPRETED BY**  
Nele Eley, DVM  
Dr. med. Vet. DipECVDI

**HOSPITAL NAME**  
Animal Surgical Center

**REFERRING VET**  
Dr. Short

**INVOICE**  
51390

**DATE**  
4-7-22

Cujo presented for sinus issues. This was first noted 16 weeks and grew over this period. Initially signs were on the right side only but now owners are seeing discharge from the left nostril. Cujo responded to antibiotic medication partially but signs have not completely cleared. Previous diagnostics were obtained and revealed normal flora on most recent nasal culture. He is indoor only and there are other cats in the household, including exposure to a younger cat that had URI signs. He is otherwise healthy  
Abnormal PE/Chem/CBC/UA Results: K high Na: K ratio low cl low TCO2 low

**COMPUTED TOMOGRAPHIC STUDY OF THE HEAD, NECK, & THORAX**

Post contrast study available for review.

**COMPUTED TOMOGRAPHIC FINDINGS**

**Head**

A large ill-defined irregular shaped soft tissue attenuating mass is seen within the left nasal cavity. The mass occupies most of the left nasal cavity and presents polyostotic aggressive bone lysis of the left bony orbita, left maxillary and nasal bones, palatinal, hard palate, and nasal septum allowing for extension of the soft tissue mass into the medial and rostral aspect of the left orbita, nasal fundus, and right nasal cavity. Extensive regional turbinate destruction is noted. The cribriform plate is intact. Mass measurements can only be approximated, however the mass measures approximately 4.5 cm in length and 2.5 cm in diameter. The left frontal sinus is filled with fluid attenuating contrast negative material. Part of the right frontal sinus is filled with similarly fluid attenuating material as well.

Bilateral medial retropharyngeal and submandibular lymphadenomegaly is seen.

**Neck**

Both lobes of the thyroid gland are included and present within normal limits.

The remainder of the soft tissue in the neck present within normal limits.

Number, alignment, and anatomy of the cervical and thoracic vertebrae present within normal limits.

**Thorax**

The sternal, cranial mediastinal and tracheobronchial lymph nodes are small elongated with a normal short-to-long-axis-ratio is < 0.5, the attenuation and contrast enhancement pattern are uniform and considered within normal limits.

The cardiovascular structures including the pulmonary vasculature are within normal limits.

A moderate generalized bronchial lung pattern with even distribution is noted throughout the lung. No evidence of interstitial pulmonary nodules is seen.

Small incidental gas pockets are seen within the esophageal lumen, there is no evidence of



**PATIENT** abnormal dilation.

Cujo Julian

**COMPUTED TOMOGRAPHIC DIAGNOSIS**

**SPECIES**

Feline

- Soft tissue mass within the left nasal cavity with aggressive biological behavior and extension into the nasal fundus, left orbita, and right nasal cavity.
- Bilateral obstructive frontal sinusitis.
- Mild bilaterally symmetric submandibular and medial retropharyngeal lymphadenomegaly.
- No evidence of pulmonary metastatic disease.
- Bronchial lung pattern suggesting chronic lower airway disease.

**BREED**

DHS

**SEX**

MN

**AGE**

13 Years

**INTERPRETATION OF THE FINDINGS & FURTHER RECOMMENDATIONS**

The CT study reveals a malignant soft tissue neoplasia within the left nasal cavity with extension into the left orbita, nasal fundus, and right nasal cavity. differential diagnosis includes lymphosarcoma, adenocarcinoma, other carcinoma, and less likely soft tissue sarcoma. Final diagnosis would require sampling for histology which could be obtained by means of rhinoscopy if the owners were interested in pursuing palliative tumor treatment. Tumor growth is extensive. Intracranial extension however is not noted at this point.

The lymph node changes are suggestive for reactive hyperplasia; however, early metastatic disease cannot be ruled out and further definition by means of fine needle aspiration is recommended.

**INTERPRETED BY**

Nele Eley, DVM  
Dr. med. Vet. DipECVDI

**HOSPITAL NAME**

Animal Surgical  
Center

**REFERRING VET**

Dr. Short

**INVOICE**

51390

**DATE**

4-7-22



**PATIENT**

Cujo Julian

**SPECIES**

Feline

**BREED**

DHS

**SEX**

MN

**AGE**

13 Years

**INTERPRETED BY**

Nele Eley, DVM  
Dr. med. Vet. DipECVDI

**HOSPITAL NAME**

Animal Surgical  
Center

**REFERRING VET**

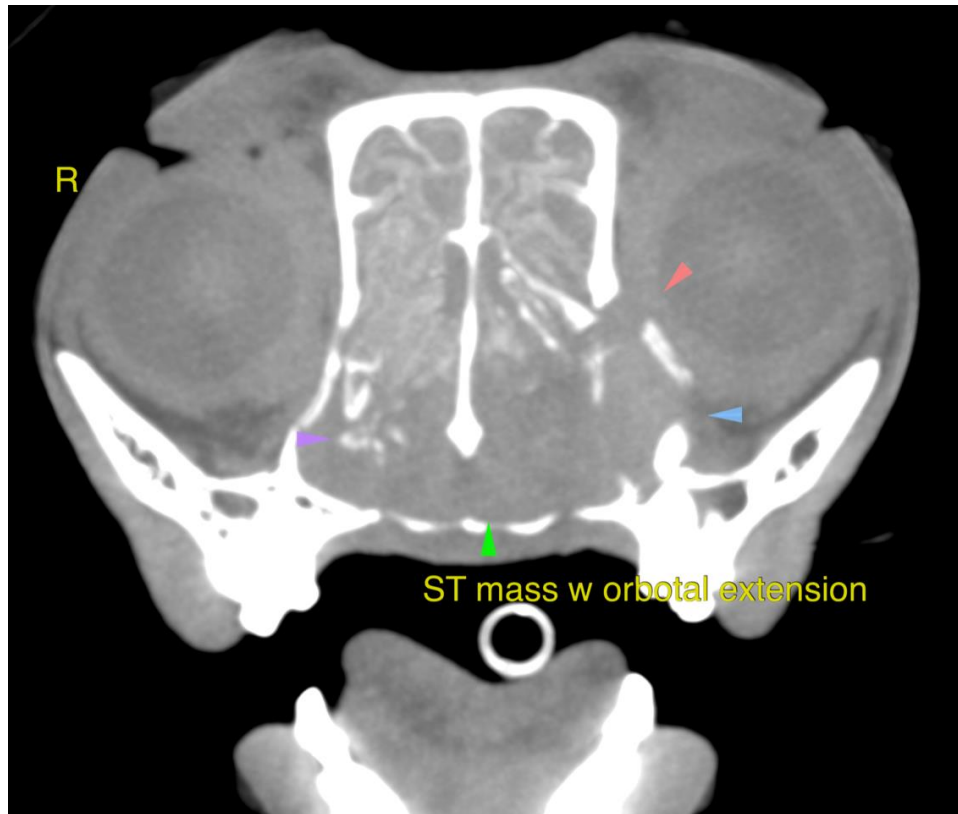
Dr. Short

**INVOICE**

51390

**DATE**

4-7-22



The information and recommendations provided are based on the images presented by the referring veterinarian/sonographer. No evaluation can be communicated regarding pathology that was not visible in the image/video clips provided.

Thank you for this referral. If the clinical or image interpretation does not parallel your findings or if I can be of any further assistance please contact me.

**Nele Eley**, DVM, Dr. med. vet., DipECVDI  
European Specialist in Veterinary Diagnostic Imaging, Cert. Radiology,  
Senior lecturer University of Giessen, Germany, Veterinary Faculty, Department of Radiology  
Nele.Eley@sonopath.com