

PATIENT

Dozer Aguinaldo

SPECIES

Canine

BREED

Rottweiler Mix

SEX

MN

AGE

10Y, 8M

WEIGHT

26.4kg

INTERPRETED BY

Nele Eley (Ondreka),
DVM Dr. med. vet.,
DipECVDI

IMAGING PERFORMED BY

Janice

HOSPITAL NAME

Bridgwater Veterinary
Hospital and Wellness
Centre

REFERRING VET

Dr. J. Shapera

INVOICE

74482

DATE

4-6-26

PRESENTING CLINICAL SIGNS

- Previous perianal mass removed with clean margins
- Now has a very large and locally invasive perianal mass that is painful, consistent straining and vomiting
- Mass extends deep into the pelvic canal, unsure how far as it extends beyond reach

Abnormal PE/Chem/CBC/UA Results: Slightly increased ALT 149 U/L, amyl 1782 U/L

COMPUTED TOMOGRAPHIC STUDY OF THE ABDOMEN

Plain and post contrast studies are available for review.

COMPUTED TOMOGRAPHIC FINDINGS

A large, irregular shaped, soft tissue attenuating mass of 8 x 6 cm is located at the position of the left anal gland. Nonuniform contrast enhancement is noted. No discrete mineralization is seen within the mass.

The left medial iliac and hypogastric lymph nodes are markedly enlarged measuring up to 5 x 3 cm.

Mild mesenteric lymphadenomegaly is noted.

Small nodular foci are present in the spleen.

Both kidneys present within normal limits for size, shape and organ architecture. After contrast administration, a bilaterally symmetric and uniform nephro- and pyelogram is noted.

The adrenal glands are within normal limits for size, shape and organ architecture.

The liver presents with normal shape, even surface, uniformly attenuating parenchyma and homogeneous contrast enhancement, unremarkable.

COMPUTED TOMOGRAPHIC DIAGNOSIS

- Large locally invasive left perianal mass meeting neoplastic criteria.
- Severe regional lymphadenopathy of the left medial iliac and hypogastric lymph nodes -highly suspicious for metastatic disease.
- Mild mesenteric lymphadenopathy.
- Splenic nodules.

INTERPRETATION OF FINDINGS & FURTHER RECOMMENDATIONS

The findings are consistent with a locally invasive perianal / anal sac mass. Given the marked enlargement of the left medial iliac and hypogastric lymph nodes, there is strong suspicion for regional metastasis.

The mesenteric lymphadenomegaly is mild and may reflect reactive changes and less likely early metastatic involvement.

Differential considerations include recurring anal sac adenocarcinoma or other soft tissue neoplasia.

The small splenic nodules are nonspecific and likely to represent benign lymphoid hyperplasia or extramedullary hematopoiesis. Metastatic disease is highly unlikely but cannot be completely



PATIENT

Dozer Aguinaldo

SPECIES

Canine

BREED

Rottweiler Mix

SEX

MN

AGE

10Y, 8M

WEIGHT

26.4kg

INTERPRETED BY

Nele Eley (Ondreka),
DVM Dr. med. vet.,
DipECVDI

IMAGING PERFORMED BY

Janice

HOSPITAL NAME

Bridgwater Veterinary
Hospital and Wellness
Centre

REFERRING VET

Dr. J. Shapera

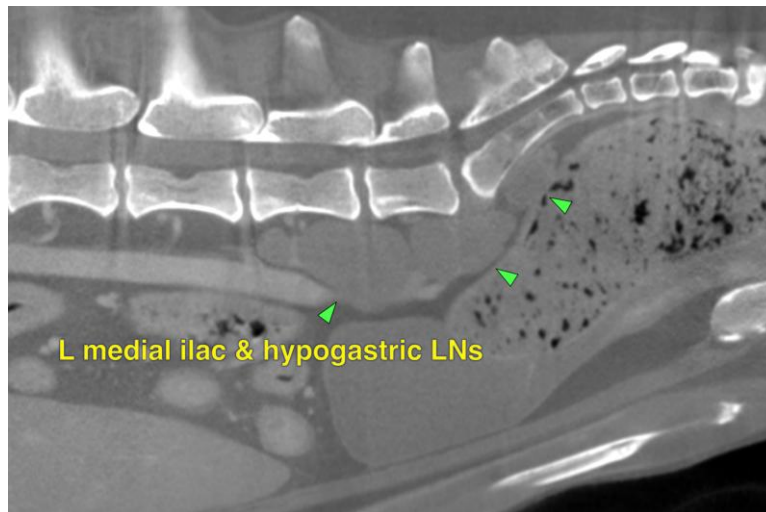
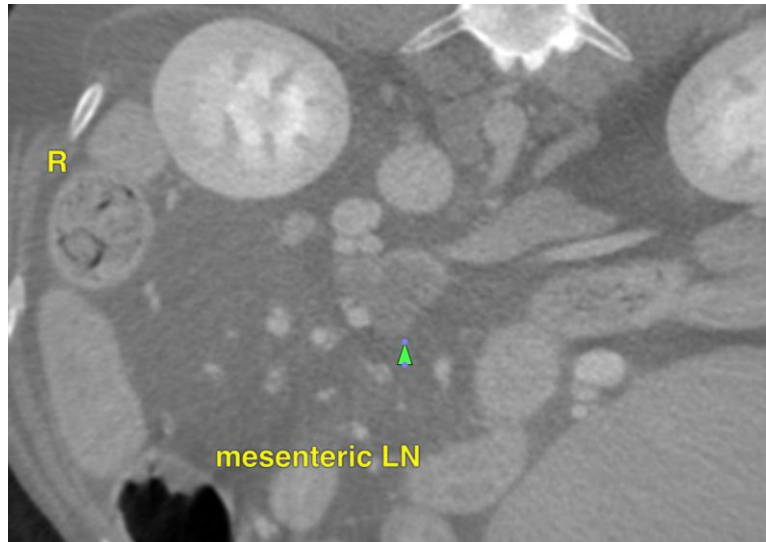
INVOICE

74482

DATE

4-6-26

excluded. Consider surgical/oncology consult for planning of mass excision and regional lymph node management. FNA or biopsy under ultrasonographic guidance of the lymph nodes and the mass can be considered for staging and confirmation of metastasis.





PATIENT

Dozer Aguinaldo

SPECIES

Canine

BREED

Rottweiler Mix

SEX

MN

AGE

10Y, 8M

WEIGHT

26.4kg

INTERPRETED BY

Nele Eley (Ondreka),
DVM Dr. med. vet.,
DipECVDI

IMAGING PERFORMED BY

Janice

HOSPITAL NAME

Bridgwater Veterinary
Hospital and Wellness
Centre

REFERRING VET

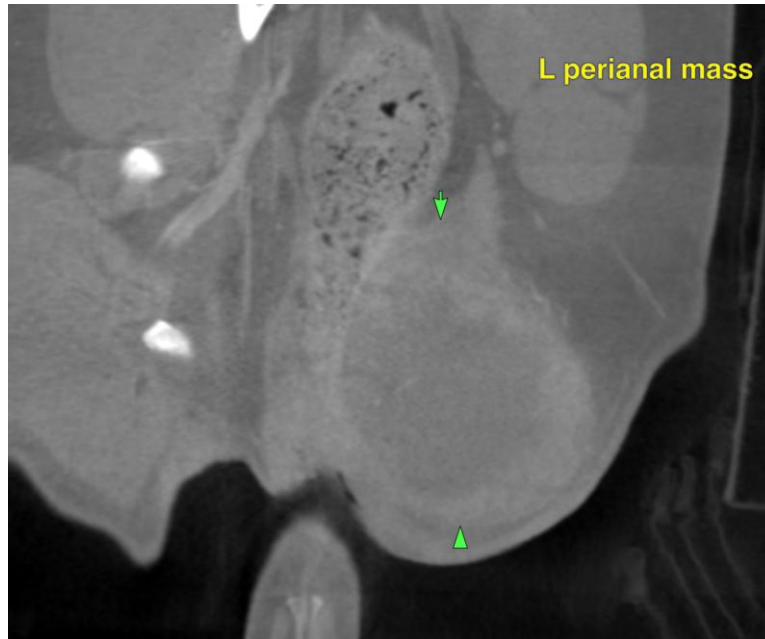Dr. J. Shapera

INVOICE

74482

DATE

4-6-26



The information and recommendations provided are based on the images presented by the referring veterinarian. No evaluation can be communicated regarding pathology that was not visible in the image/video clips provided.

Thank you for this referral. If the clinical or image interpretation does not parallel your findings or if I can be of any further assistance please contact me.

Nele Eley (Ondreka), DVM, Dr. med. vet., DipECVDI
European Specialist in Veterinary Diagnostic Imaging, Cert. Radiology,
Senior lecturer University of Giessen/Germany, Veterinary Faculty, Department of Radiology.
info@sonopath.com