

PATIENT PRESENTING CLINICAL SIGNS

Scooter Lorry

1. Weight loss with ravenous appetite, no v/d 2. Diabetic 3. PU/PD
Abnormal PE/Chem/CBC/UA Results: 1. Weight loss with ravenous appetite, no v/d 2. Diabetic 3. PU/PD 4. Gall bladder sludge- u/s 3/2023: The gallbladder is unchanged. The luminal echogenic material in the gallbladder may be atypical incidental gallbladder sludge. Impending gallbladder mucocele formation is not entirely excluded, but the gallbladder wall is unremarkable on the current study. 5. U/S 3/2023: The anechoic distally enhancing structure in the liver is likely a degenerative cyst. 6. U/S 3/2023: There is a small amount of peritoneal effusion. Consideration is given to modified transudate associated with disease hepatobiliary structures, exudate such as with pancreatitis or hepatitis, or less likely transudate secondary to hypoalbuminemia. 7. U/S 3/2023: The spleen is enlarged and hypoechoic. Differentials include extramedullary hematopoiesis, lymphoid hyperplasia, infectious/inflammatory disease, or neoplasia. The hyperechoic foci throughout the spleen may be due to dystrophic mineralization such as with hyperadrenocorticism. 8. U/S 3/2023: There is evidence of bilateral nephrocalcinosis. This is likely an incidental finding. 9. U/S 3/2023: The small hyperechoic structure in the urinary bladder is still most consistent with a small calculus. 10. U/S 3/2023: The B-lines seen in the caudal thorax may be due to areas of atelectasis, fibrosis, or less likely pulmonary edema or nodules in lungs.

SPECIES

Canine

BREED

Miniature Poodle

SEX

Neutered Male

COMPUTED TOMOGRAPHIC STUDY OF THE HEAD, THORAX, & ABDOMEN

AGE

12 Years, 2 Months

Plain and post-contrast studies of the head and abdomen and post-contrast study of the thorax available for review.

COMPUTED TOMOGRAPHIC FINDINGS

INTERPRETED BY

Nele Eley (Ondreka),
DVM Dr. med. vet.,
DipECVDI

Head

The brain presents no deviation from normal anatomy and symmetry. The grey and white matter distinction and the neuroparenchymal attenuation are as expected. The distribution of contrast enhancement is within normal limits throughout the parenchyma and meninges. The ventricular system is non-dilated and within the limits of the expected volume and symmetry. The pituitary gland presents within normal limits. No evidence of pituitary gland enlargement is seen.

HOSPITAL NAME

Mobile Pet Imaging

Thin and smoothly folded conchae and turbinates with even smooth mucosal lining. The osseous lining of the nasal cavities is intact.

REFERRING VET

Meaux

Both temporomandibular joints present congruent joint spaces with even subchondral bone surfaces and are considered within normal limits.

Both tympanic bullae are aerated, the mucosal lining is not seen, the bony wall is smooth and thin. The external auditory meatuses present within normal limits.

INVOICE

57672

The submandibular and medial retropharyngeal lymph nodes are small and elongated with a normal short-to-long-axis-ratio is < 0.5, the attenuation and contrast enhancement pattern is uniform.

The salivary glands present within normal limits.

DATE

4-6-23

The visible dentition is within normal limits.



PATIENT Both lobes of the thyroid gland and the cervical lymph nodes present within normal limits.
Thorax

Scooter Lorry

The sternal, cranial mediastinal and tracheobronchial lymph nodes are small elongated with a normal short-to-long-axis-ratio is < 0.5, the attenuation and contrast enhancement pattern are uniform and considered within normal limits.

SPECIES

Canine

The cardiovascular structures including the pulmonary vasculature are within normal limits.

BREED

Miniature Poodle

The bronchial tree presents with regular branching and tapers uniformly towards the periphery as expected, the bronchial walls are thin and smooth. The bronchus-to-artery ratio is within normal limits.

The lung parenchyma presents the expected architecture and attenuation behavior.

SEX

Neutered Male

Small incidental gas pockets are seen within the esophageal lumen, there is no evidence of abnormal dilation.

Abdomen

The serosal fat presents normal attenuation behavior. There is no evidence of peritoneal effusion or peritonitis.

AGE

12 Years, 2 Months

Small mineral attenuating foci are seen within the bilateral renal diverticuli.

No evidence of mineral attenuating material is seen within the urinary bladder.

INTERPRETED BY

Nele Eley (Ondreka),
DVM Dr. med. vet.,
DipECVDI

The adrenal glands are within normal limits for size, shape and organ architecture.

The spleen presents mild generalized enlargement with contracted appearance, cortication, and rounding of the splenic margins without scalloping or a significant mass effect. The contrast enhancement pattern of the spleen is uniform.

HOSPITAL NAME

Mobile Pet Imaging

Moderate generalized enlargement of the liver is noted. The gallbladder is severely distended and presents layered immobile content which is mineral attenuating in varying degrees and fixed in the center of the gallbladder. The layers of the gallbladder content are uniformly hypoattenuating. All of the gallbladder content is contrast negative. The cystic duct and common bile duct are dilated. No evidence of obstruction of the extrahepatic biliary system is seen.

REFERRING VET

Meaux

The pancreas presents mild generalized enlargement. No evidence of regional mesenteropathy is seen.

The position, delineation, wall and content of the gastrointestinal tract are considered within normal limits throughout.

INVOICE

57672

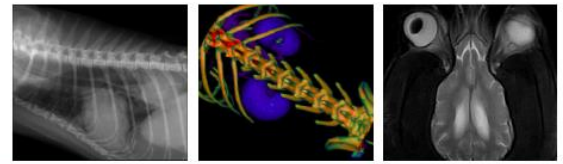
Moderate organized and mineralized T13/L1 extrusion with collapsed intervertebral disc space, vertebral endplate sclerosis, and spondylosis deformans is seen.

COMPUTED TOMOGRAPHIC DIAGNOSIS

DATE

4-6-23

- Normal CT findings of the pituitary gland and adrenal glands.
- Moderate generalized hepatomegaly



PATIENT

Scooter Lorry

- Suspect gallbladder mucocele.
- Mild common bile duct dilation.
- Pancreatopathy.
- Splenopathy with mild splenomegaly and cortication.
- Bilateral nephrocalcinosis with no evidence of pyelectasia or obstruction.
- Moderate chronic intervertebral disc extrusion T13/L1.

SPECIES

Canine

INTERPRETATION OF FINDINGS & FURTHER RECOMMENDATIONS

BREED

Miniature Poodle

The CT study reveals moderate generalized hepatomegaly. Vacuolar, endocrine, and metabolic hepatopathy are primary differential diagnoses. Hepatitis and a diffuse neoplastic infiltrate cannot be ruled out entirely.

SEX

Neutered Male

The findings of the gallbladder are highly suggestive for a gallbladder mucocele. No evidence of rupture or regional peritonitis is seen at this point. Nevertheless, the gallbladder appears to be very distended and cystic as well as common bile duct dilation are seen as well.

AGE

12 Years, 2 Months

The findings of the pancreas suggest potential for chronic pancreatitis. Benign nodular hyperplasia is a potential differential diagnosis.

The findings of the spleen are most suggestive for lymphoid hyperplasia or extramedullary hematopoiesis. Splenitis and neoplastic infiltrate are thought less likely but can never be ruled out entirely.

INTERPRETED BY

Nele Eley (Ondreka),
DVM Dr. med. vet.,
DipECVDI

HOSPITAL NAME

Mobile Pet Imaging

REFERRING VET

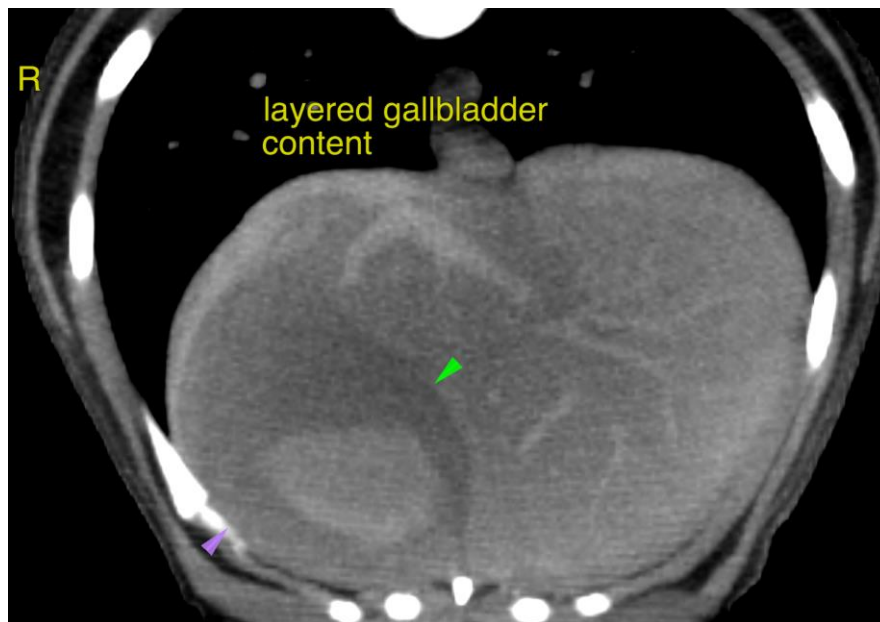
Meaux

INVOICE

57672

DATE

4-6-23





PATIENT

Scooter Lorry

SPECIES

Canine

BREED

Miniature Poodle

SEX

Neutered Male

AGE

12 Years, 2 Months

INTERPRETED BY

Nele Eley (Ondreka),
DVM Dr. med. vet.,
DipECVDI

HOSPITAL NAME

Mobile Pet Imaging

REFERRING VET

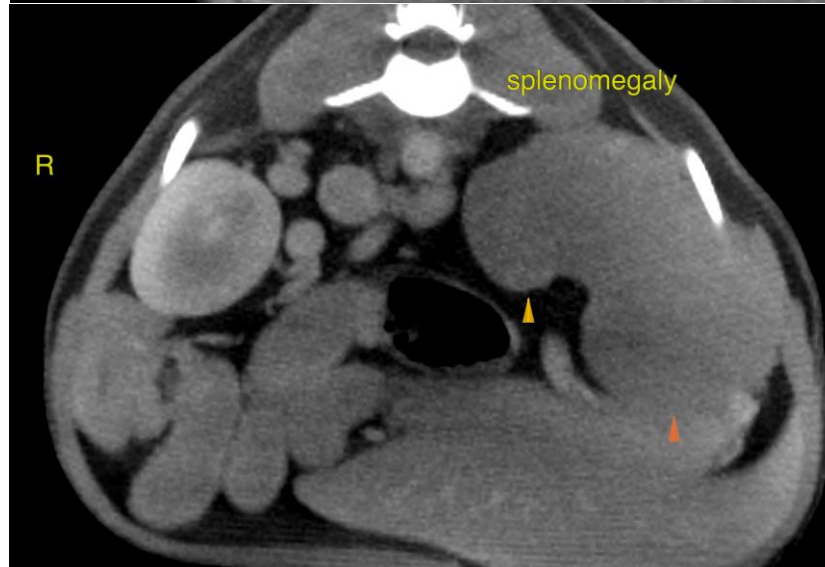
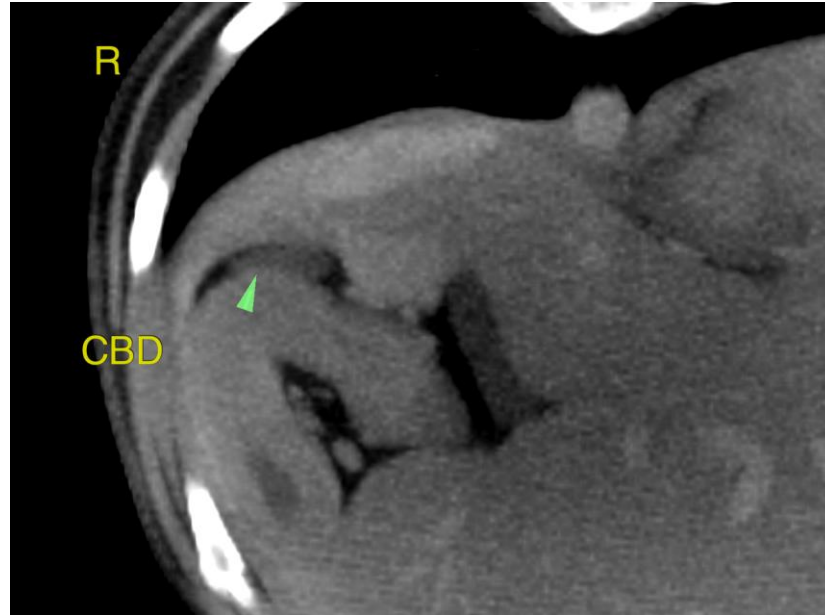
Meaux

INVOICE

57672

DATE

4-6-23



The information and recommendations provided are based on the images presented by the referring veterinarian. No evaluation can be communicated regarding pathology that was not visible in the image/video clips provided.

Thank you for this referral. If the clinical or image interpretation does not parallel your findings or if I can be of any further assistance please contact me.

Nele Eley (Ondreka), DVM, Dr. med. vet., DipECVDI
European Specialist in Veterinary Diagnostic Imaging, Cert. Radiology,
Senior lecturer University of Giessen/Germany, Veterinary Faculty, Department of Radiology.
Nele.Eley@sonopath.com