



**PATIENT PRESENTING CLINICAL SIGNS**

**Max Nguyen**  
 P presents for vomiting starting at 1 am. o states p vomited 2x all the food he ate for dinner, then again at 6 am just bile, and at 7am o took p outside and p has some blood in stool and 1 more episode of vomiting bile. Per o p has separation anxiety and mom has been out of own since Saturday. p did not get anything new and is not the type to get into things.

**SPECIES**

Canine

**BREED**

Bichon

Abnormal PE/Chem/CBC/UA Results: Hydration: Appropriately hydrated Mentation: BAR EENT: No nasal discharge; clear no discharge OU; clean no exudate AU; No cough on tracheal palpation. Oral Cavity: mod dental tartar present Lymph Nodes: Symmetrical, no changes in size, shape, consistency Skin: Good hair coat, no signs of ectoparasites. No lesions noted. CV/Respiratory: No murmur or crackles/wheezing auscultated. Synchronous pulses, normal rate. Normal bronchovesicular sounds. Abd/GI: Soft non painful abdomen, no organomegaly, no abnormalities on abdominal palpation Uro/Perineum: N Musculoskeletal: Ambulatory x4, no lameness noted. No pain on palpation of limbs. BCS 5/9 Neurological: Appropriate Fecal: NPS

**SEX**

MN

**RADIOGRAPHIC STUDY OF THE ABDOMEN**

Right lateral and ventrodorsal views of the abdomen totaling 2 images available for review.

**RADIOGRAPHIC FINDINGS**

**AGE**

4 Years

The surrounding bony structures are within normal limits.

No abnormalities of the extraabdominal soft tissues are noted. The abdominal wall is smooth and thin.

**INTERPRETED BY**

Nele Eley, DVM  
 Dr. med. Vet. DipECVDI

The serosal detail is maintained throughout the peritoneal and retroperitoneal space.

The liver is appropriate in position, size and presents uniform opacity.

**HOSPITAL NAME**

DPC Veterinary  
 Hospital

The splenic head is in the anticipated position and within normal limits for size and opacity. The splenic body and tail are considered normal for position, size, shape and opacity.

Both kidneys are seen and present with normal size, shape, delineation and opacity. The urinary bladder is in its anticipated position. No radiopaque calculi are noted throughout the upper and lower urinary tract.

**REFERRING VET**

Dr. White

The stomach is empty except for a mild amount of gas.

The small intestinal loops are turgid in appearance. However, present no evidence of abnormal dilation, plication, or radiopaque foreign material.

**INVOICE**

51374

The colon and cecum are largely empty except for gas and a mild amount of fecal material within the descending colon.

**RADIOGRAPHIC DIAGNOSIS**

**DATE**

4-6-22

- Gastrointestinal maldigestion pattern with no radiographic signs of mechanical ileus.



**PATIENT**

Max Nguyen

**INTERPRETATION OF THE FINDINGS & FURTHER RECOMMENDATIONS**

The radiographic study reveals no evidence of complete mechanical ileus. The findings are more suggestive for functional ileus. Subileus cannot be ruled out entirely. Consider recheck radiographs or ultrasound for further definition should the patient's clinical signs persist or deteriorate.

**SPECIES**

Canine

**BREED**

Bichon

**SEX**

MN

**AGE**

4 Years

**INTERPRETED BY**

Nele Eley, DVM  
Dr. med. Vet. DipECVDI

**HOSPITAL NAME**

DPC Veterinary  
Hospital

**REFERRING VET**

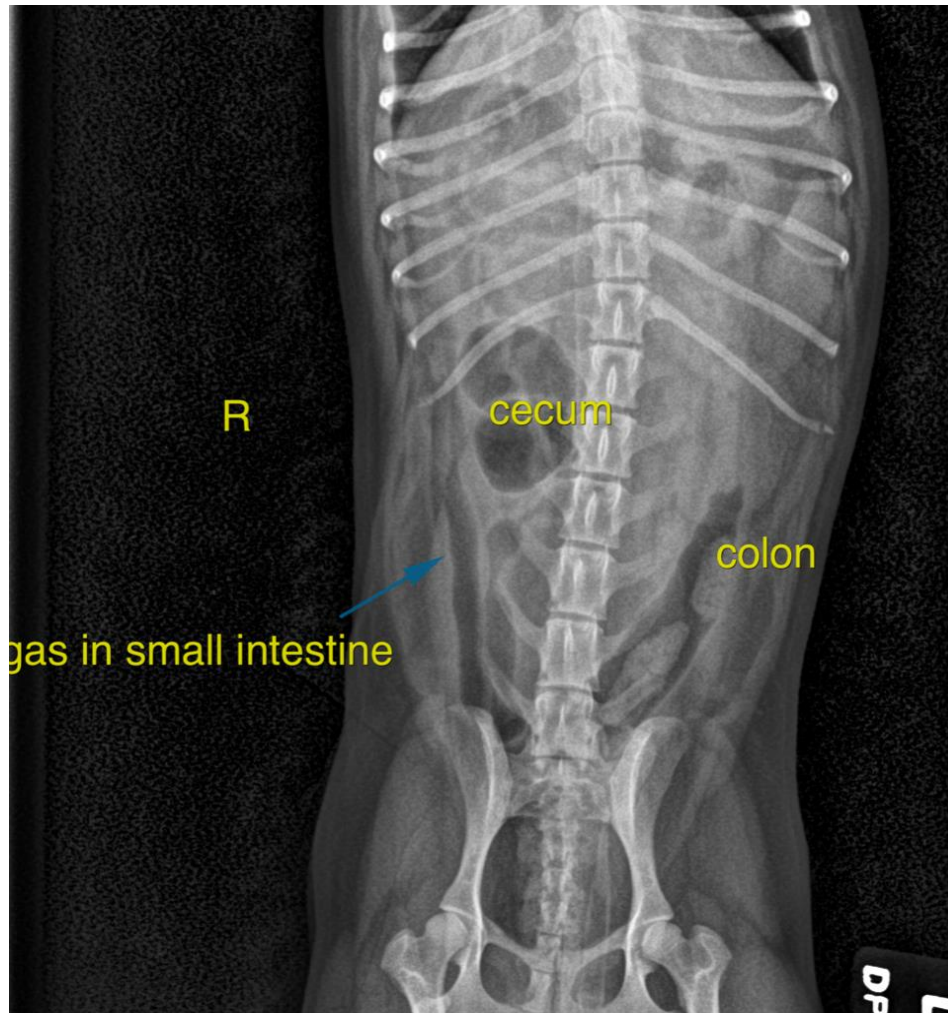
Dr. White

**INVOICE**

51374

**DATE**

4-6-22





#### PATIENT

Max Nguyen

The information and recommendations provided are based on the images presented by the referring veterinarian/sonographer. No evaluation can be communicated regarding pathology that was not visible in the image/video clips provided.

#### SPECIES

Canine

Thank you for this referral. If the clinical or image interpretation does not parallel your findings or if I can be of any further assistance please contact me.

#### BREED

Bichon

**Nele Eley**, DVM, Dr. med. vet., DipECVDI  
European Specialist in Veterinary Diagnostic Imaging, Cert. Radiology,  
Senior lecturer University of Giessen, Germany, Veterinary Faculty, Department of Radiology  
Nele.Eley@sonopath.com

#### SEX

MN

#### AGE

4 Years

#### INTERPRETED BY

Nele Eley, DVM  
Dr. med. Vet. DipECVDI

#### HOSPITAL NAME

DPC Veterinary  
Hospital

#### REFERRING VET

Dr. White

#### INVOICE

51374

#### DATE

4-6-22