



PATIENT

Goldie Coco

PRESENTING CLINICAL SIGNS

Goldie presented for left hind limb lameness/bilateral limb lameness. Pet was seen last year for right hind leg. TPLO was recommended for RHL. O is now concerned about left hind as another vet was palpating leg vet mentioned possible ACL tear.

SPECIES

Canine

RADIOGRAPHIC STUDY OF THE STIFLES

Mediolateral and craniocaudal views of both stifles totaling 4 images available for review.

BREED

Golden Retriever

RADIOGRAPHIC FINDINGS

Right Stifle

The muscle volume appears to be decreased in the right hind limb. The bones present a mild overall decrease in opacity.

SEX

FS

There is severe articular swelling of the right stifle joint. An isolated bone opacity of 1 x 0.5 cm is seen in the cranial aspect of the femoral tibial joint.

AGE

6 Years

The periarticular margins present a large amount of osteophytes accentuating the femoral trochlea, proximal and distal poles of the patella, and cranial and caudal margins of the tibial plateau.

INTERPRETED BY

Nele Eley, DVM
Dr. med. Vet. DipECVDI

Enthesophytes are seen at the distal end of the patella tendon. Proximal and distal ends of the patella tendon present mild thickening.

Extensive intercondylar bone remodeling is seen in the distal femur.

There is no evidence of cranial thrust of the tibia.

HOSPITAL NAME

Animal Surgical
Center

Left Stifle

The left stifle joint presents severe articular swelling. Presence of multiple small gas bubbles is seen cranial to the femoral tibial joint level with the infrapatellar fat pad.

There is wet fur artifact.

REFERRING VET

Woodbury Animal
Hospital

A mild amount of periarticular osteophytes is present.

No evidence of cranial thrust of the tibia is seen.

There is bone remodeling in the intercondylar groove of the distal femur.

INVOICE

51381

RADIOGRAPHIC DIAGNOSIS

- Severe chronic degenerative joint disease of the right stifle with synovial osteochondromatosis and severe osteoarthritic changes.
- Articular swelling, mild osteoarthritic findings, and soft tissue emphysema of the left stifle.

DATE

4-6-22



PATIENT

Goldie Coco

SPECIES

Canine

BREED

Golden Retriever

SEX

FS

AGE

6 Years

INTERPRETED BY

Nele Eley, DVM
Dr. med. Vet. DipECVDI

HOSPITAL NAME

Animal Surgical
Center

REFERRING VET

Woodbury Animal
Hospital

INVOICE

51381

DATE

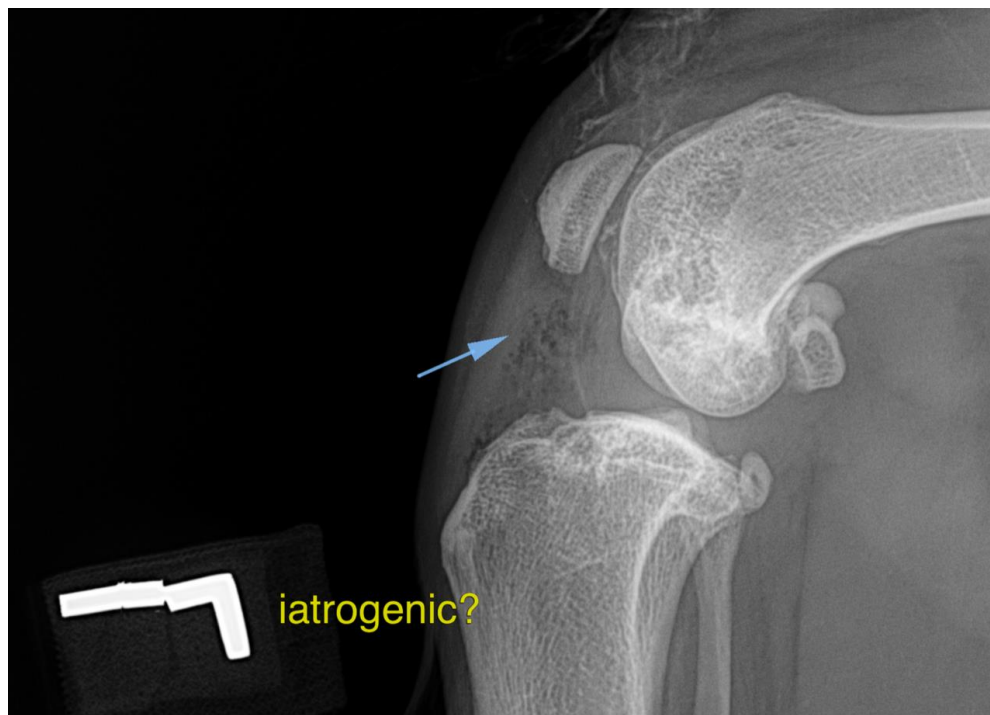
4-6-22

INTERPRETATION OF THE FINDINGS & FURTHER RECOMMENDATIONS

The radiographic study reveals severe chronic osteoarthritis of the right stifle joint. Cranial thrust of the tibia cannot be seen. Consider presence of chronic active inflammation with formation of synovial osteochondroma in the cranial aspect of the femoral tibial joint. Chronic cranial cruciate ligament injury, meniscopathy, prior trauma, and arthritis including immune mediated all are a potential. Correlate with the clinical palpation.

The left stifle presents mild osteoarthritic changes. Again here, one of the most common underlying causes is cranial cruciate ligament injury. Correlation with the clinical palpation is required. Sedated palpation, ultrasound, or MRI could be used for further definition should the clinical palpation remain unclear at this point.

The soft tissue emphysema is likely iatrogenic due to arthrocentesis. Otherwise, traumatic injury and infection with gas forming bacteria would have to be considered.





PATIENT

Goldie Coco

The information and recommendations provided are based on the images presented by the referring veterinarian/sonographer. No evaluation can be communicated regarding pathology that was not visible in the image/video clips provided.

Thank you for this referral. If the clinical or image interpretation does not parallel your findings or if I can be of any further assistance please contact me.

SPECIES

Canine

Nele Eley, DVM, Dr. med. vet., DipECVDI
European Specialist in Veterinary Diagnostic Imaging, Cert. Radiology,
Senior lecturer University of Giessen, Germany, Veterinary Faculty, Department of Radiology
Nele.Eley@sonopath.com

BREED

Golden Retriever

SEX

FS

AGE

6 Years

INTERPRETED BY

Nele Eley, DVM
Dr. med. Vet. DipECVDI

HOSPITAL NAME

Animal Surgical
Center

REFERRING VET

Woodbury Animal
Hospital

INVOICE

51381

DATE

4-6-22