



PATIENT

Fluffy Elcik

PRESENTING CLINICAL SIGNS

Saturday night, the pet had an episode, o thought it was a stroke, lasted between 3-5 minutes, the head was crooked she was walking in circles, they brought her to emergency. Report in documents. Pet had another episode on Monday night, lasted less than 5 minutes, legs were not working

SPECIES

Canine

RADIOGRAPHIC STUDY OF THE THORAX & ABDOMEN

Right/lateral and ventrodorsal views of the thorax and abdomen totaling 4 images available for review.

BREED

Maltese

RADIOGRAPHIC FINDINGS

Abdomen

The patient is obese.

SEX

Spayed

The abdomen is potbellied in appearance with far ventral excursion of the ventral abdominal wall.

AGE

12 Years

Moderate enlargement of the liver with rounded lobar margins is noted and appears to accentuate the right division of the liver.

The stomach is post prandial and presents moderate aerophagia.

INTERPRETED BY

Nele Eley, DVM
Dr. med. Vet. DipECVDI

Extensive mineralization of the renal diverticuli is seen in both kidneys.

The radiographic presentation of the spleen, small and large intestine, as well as the urinary bladder is within normal limits.

Mild lumbosacral spondylosis deformans is seen.

HOSPITAL NAME

Animal Paradise
Hospital

Thorax

One elbow presents mild osteoarthritic changes.

The thoracic volume is rather small.

REFERRING VET

Dr. Elshafie

The vertebral heart score is 10. No specific chamber enlargement and no overall cardiomegaly is seen.

The lung presents a mild generalized bronchointerstitial pattern which may well be within age related normal limits.

INVOICE

51405

Redundancy of the dorsal tracheal ligament of the cervical trachea is noted.

There is mild esophageal aerophagia.

DATE

4-6-22



PATIENT

Fluffy Elkik

RADIOGRAPHIC DIAGNOSIS

- Obesity.
- Potbellied appearance.
- Hepatomegaly.
- Bilateral hypercalcemic nephropathy.
- Gastric aerophagia.
- Lumbosacral spondylosis.
- Redundant dorsal tracheal ligament.

SPECIES

Canine

BREED

Maltese

INTERPRETATION OF THE FINDINGS & FURTHER RECOMMENDATIONS

Consider presence of endocrine/metabolic hepatopathy such as with Cushing's, diabetogenic, degenerative vacuolar hepatopathy, or other. Diffuse hepatitis and diffuse infiltrative disease cannot be ruled out entirely as a differential diagnosis. Correlate with the laboratory values and consider ultrasound as well as parenchymal sampling for further definition if indicated.

SEX

Spayed

The radiographic presentation of the thorax is within age related normal limits.

AGE

12 Years

INTERPRETED BY

Nele Eley, DVM
Dr. med. Vet. DipECVDI

HOSPITAL NAME

Animal Paradise
Hospital

REFERRING VET

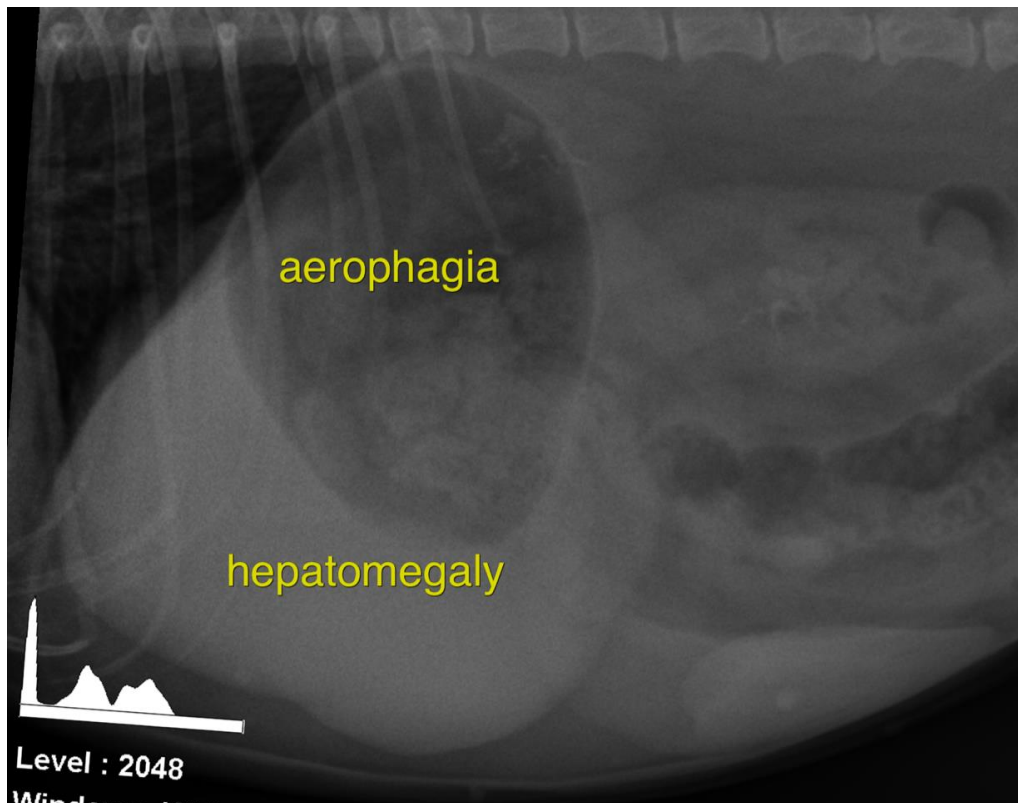
Dr. Elshafie

INVOICE

51405

DATE

4-6-22





PATIENT

Fluffy Elkik

The information and recommendations provided are based on the images presented by the referring veterinarian/sonographer. No evaluation can be communicated regarding pathology that was not visible in the image/video clips provided.

SPECIES

Canine

Thank you for this referral. If the clinical or image interpretation does not parallel your findings or if I can be of any further assistance please contact me.

BREED

Maltese

Nele Eley, DVM, Dr. med. vet., DipECVDI
European Specialist in Veterinary Diagnostic Imaging, Cert. Radiology,
Senior lecturer University of Giessen, Germany, Veterinary Faculty, Department of Radiology
Nele.Eley@sonopath.com

SEX

Spayed

AGE

12 Years

INTERPRETED BY

Nele Eley, DVM
Dr. med. Vet. DipECVDI

HOSPITAL NAME

Animal Paradise
Hospital

REFERRING VET

Dr. Elshafie

INVOICE

51405

DATE

4-6-22