



PATIENT

Brandon Camacho

PRESENTING CLINICAL SIGNS

Acute of blindness and seizures. PE: blindness/ no menace/seizures
 Abnormal PE/Chem/CBC/UA Results: CBC --- mild anemia, monocytosis CHEM --- GLOB mild increased Snap 4Dx: negative for all

SPECIES

Canine

COMPUTED TOMOGRAPHIC STUDY OF THE HEAD

Plain and post contrast studies available for review.

BREED

Mixed Large Breed

COMPUTED TOMOGRAPHIC FINDINGS

An irregular shaped strongly enhancing mass of approximately 2.0 cm length, 1.0 cm height, and 1.0 width is seen within the third ventricle. The mass occupies and expands most of the third ventricle and appears to be associated with the choroid plexus of the third ventricle. Lesion margins are ill-defined with lobulated appearance. A left rostral extension of the mass is seen.

SEX

NM

An additional 3mm sized enhancing nodule appears to be associated with the choroid plexus on the floor of the right lateral ventricle.

AGE

6 Years

A small otolith is seen in the left tympanic bulla.

COMPUTED TOMOGRAPHIC DIAGNOSIS

- Strongly enhancing extraaxial intraventricular mass within the third ventricle.
- Additional enhancing lateral ventricle nodule - right sided.

INTERPRETED BY

Nele Eley, DVM
 Dr. med. Vet. DipECVDI

INTERPRETATION OF THE FINDINGS & FURTHER RECOMMENDATIONS

The CT findings suggest presence of intraventricular neoplasia associated with the choroid plexus. Choroid plexus carcinoma is considered most likely. The nodule within the right lateral ventricle may represent drop metastases which is common in choroid plexus carcinoma. Other differentials would include ependymoma, intraventricular meningioma, round cell neoplasia, and hemangioma/hemangiosarcoma.

HOSPITAL NAME

Veterinary Image Center

REFERRING VET

Dr. L. Ricci, DVM

INVOICE

51372

DATE

4-6-22



PATIENT

Brandon Camacho

SPECIES

Canine

BREED

Mixed Large Breed

SEX

NM

AGE

6 Years

INTERPRETED BY

Nele Eley, DVM
Dr. med. Vet. DipECVDI

HOSPITAL NAME

Veterinary Image
Center

REFERRING VET

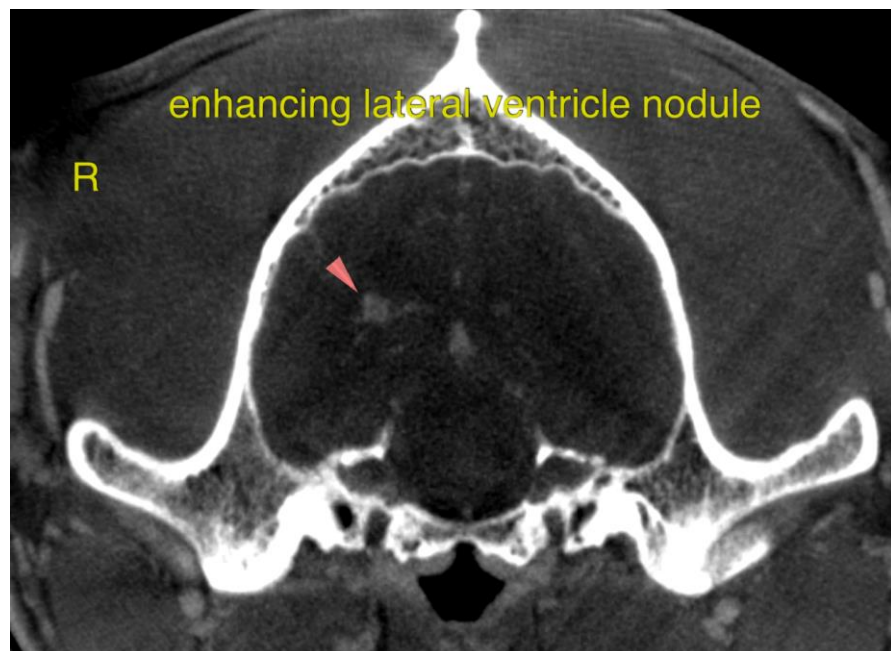
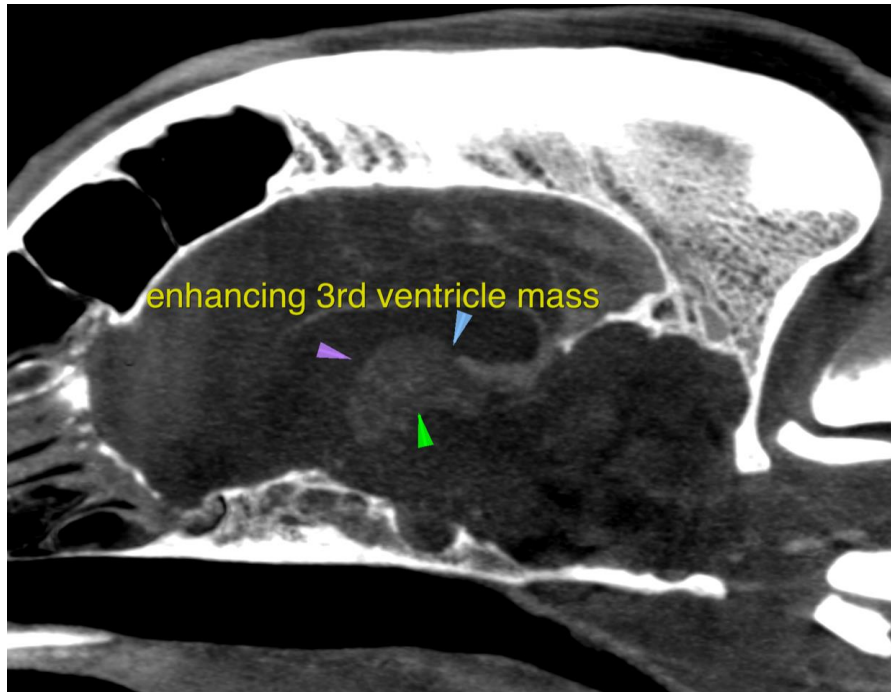
Dr. L. Ricci, DVM

INVOICE

51372

DATE

4-6-22





PATIENT

Brandon Camacho

The information and recommendations provided are based on the images presented by the referring veterinarian/sonographer. No evaluation can be communicated regarding pathology that was not visible in the image/video clips provided.

SPECIES

Canine

Thank you for this referral. If the clinical or image interpretation does not parallel your findings or if I can be of any further assistance please contact me.

BREED

Mixed Large Breed

Nele Eley, DVM, Dr. med. vet., DipECVDI
European Specialist in Veterinary Diagnostic Imaging, Cert. Radiology,
Senior lecturer University of Giessen, Germany, Veterinary Faculty, Department of Radiology
Nele.Eley@sonopath.com

SEX

NM

AGE

6 Years

INTERPRETED BY

Nele Eley, DVM
Dr. med. Vet. DipECVDI

HOSPITAL NAME

Veterinary Image
Center

REFERRING VET

Dr. L. Ricci, DVM

INVOICE

51372

DATE

4-6-22