



PATIENT

Shadow Popow

PRESENTING CLINICAL SIGNS

Presented for chronic (8 years) congestion and nasal discharge which recently has had blood in it. Acting normal otherwise
Abnormal PE/Chem/CBC/UA Results: Normal

SPECIES

Feline

COMPUTED TOMOGRAPHIC STUDY OF THE HEAD

Plain and post contrast studies available for review.

BREED

DSH

COMPUTED TOMOGRAPHIC FINDINGS

Moderate turbinate destruction is noted within both nasal cavities. The mucosal lining of the nasal cavities presents moderate irregular thickening. The mucosal lining of the remaining turbinates is uneven and thick as well. Hyperostosis, mucosal swelling, and fluid accumulation are noted within the right frontal sinus. The nasal septum presents leftward deviation. Distortion with mild osseous expansion of the nasal frontal suture of the nasal cavity is noted on the right hand side. The cribriform plate is intact.

SEX

MN

No evidence of concurrent otitis is noted.

AGE

9

The medial retropharyngeal lymph nodes and submandibular lymph nodes present bilaterally symmetric mild enlargement.

INTERPRETED BY

Nele Eley, DVM
Dr. med. Vet. DipECVDI

Hypodontia with multiple absent tooth elements is noted. Mild atrophy of the alveolar crest is noted in all quadrants of the jaw.

COMPUTED TOMOGRAPHIC DIAGNOSIS

- Moderate chronic destructive bilateral rhinosinusitis.
- Mild bilaterally symmetric submandibular and medial retropharyngeal lymphadenomegaly.

HOSPITAL NAME

Northeast Veterinary Referral Hospital

INTERPRETATION OF THE FINDINGS & FURTHER RECOMMENDATIONS

The CT study reveals moderate chronic bilateral destructive rhinosinusitis. Differential diagnosis includes infectious rhinitis such as fungal and less likely bacterial, viral, or mixed versus chronic lymphoplasmacytic rhinitis. Further definition by means of rhinoscopy with sampling is recommended if not performed already.

REFERRING VET

Dr. Runde

The lymph node changes are compatible with reactive hyperplasia.

INVOICE

57655

DATE

4-5-23



PATIENT

Shadow Popow

SPECIES

Feline

BREED

DSH

SEX

MN

AGE

9

INTERPRETED BY

Nele Eley, DVM
Dr. med. Vet. DipECVDI

HOSPITAL NAME

Northeast Veterinary
Referral Hospital

REFERRING VET

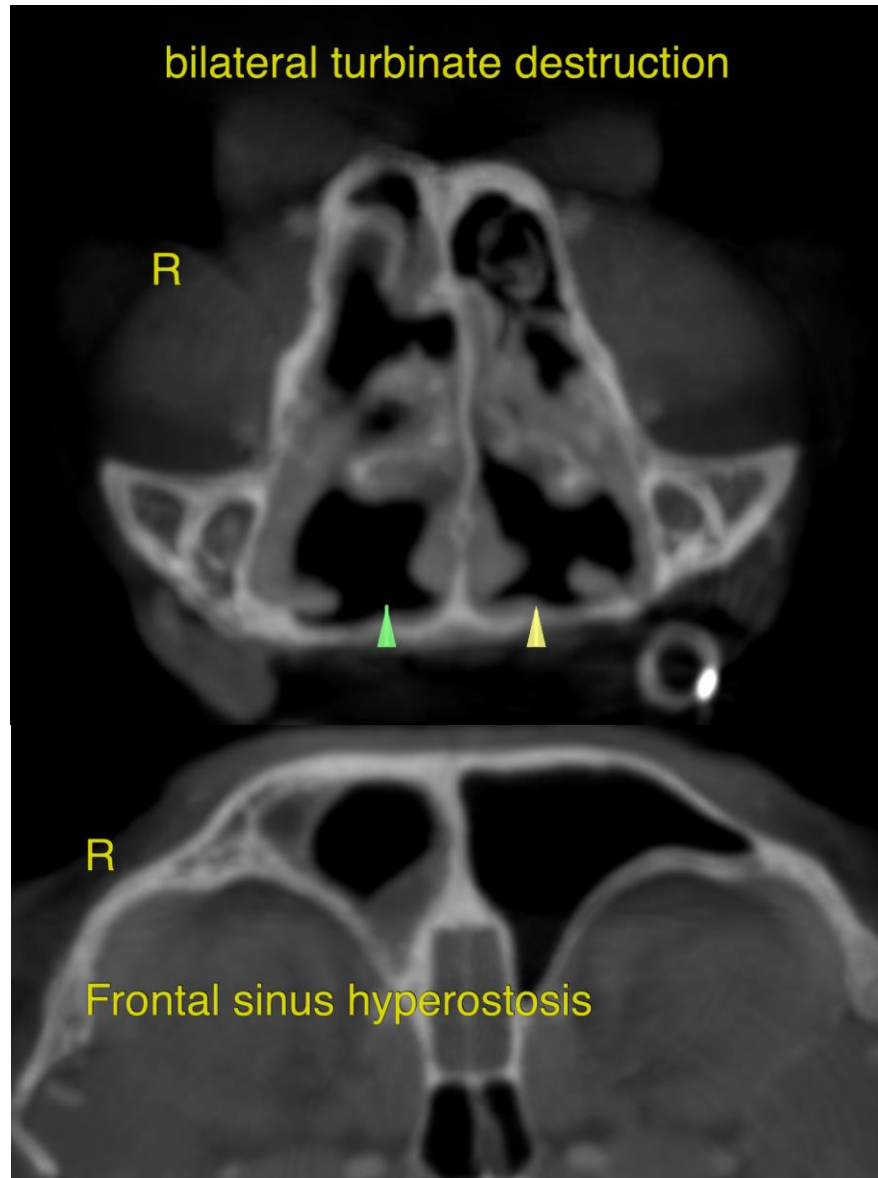
Dr. Runde

INVOICE

57655

DATE

4-5-23



The information and recommendations provided are based on the images presented by the referring veterinarian/sonographer. No evaluation can be communicated regarding pathology that was not visible in the image/video clips provided.

Thank you for this referral. If the clinical or image interpretation does not parallel your findings or if I can be of any further assistance please contact me.

Nele Eley, DVM, Dr. med. vet., DipECVDI
European Specialist in Veterinary Diagnostic Imaging, Cert. Radiology,
Senior lecturer University of Giessen, Germany, Veterinary Faculty, Department of Radiology
Nele.Eley@sonopath.com