



PATIENT

Otis Robertson

PRESENTING CLINICAL SIGNS

sudden onset of difficult breathing FELINE ASTHMA ?
Abnormal PE/Chem/CBC/UA Results: Elevated eosinophils

SPECIES

Feline

RADIOGRAPHIC STUDY OF THE THORAX

Right/left lateral and ventrodorsal views of the thorax totaling 3 images available for review.

BREED

DLH

RADIOGRAPHIC FINDINGS

The lungs are deeply inflated. The diaphragmatic cupola is flattened. The lumbodiaphragmatic and post-cardiac spaces are wide.

SEX

Male Neuter

There is a moderate generalized bronchial lung pattern with mild peribronchial cuffing and even distribution throughout the lung.

The radiographic presentation of the cardiac silhouette is considered within normal limits.

No evidence of mediastinal widening is noted.

AGE

3 Years

Course and width of the trachea are considered within normal limits.

The thoracic boundaries present within normal limits.

INTERPRETED BY

Nele Eley, DVM
Dr. med. Vet. DipECVDI

There is mild gastric aerophagia.

RADIOGRAPHIC DIAGNOSIS

- Chronic lower airway pattern with air trapping.

HOSPITAL NAME

St. Catherine's Animal
Hospital

INTERPRETATION OF THE FINDINGS & FURTHER RECOMMENDATIONS

The radiographic findings are highly suggestive for allergic lower airway syndrome/asthma. Theoretically, infectious bronchitis such as viral, bacterial, parasitic, or protozoal cannot be ruled out as a differential diagnosis. Consider a clinical trial of treatment for feline asthma versus further definition by means of airway sampling.

REFERRING VET

Dr. Boctor

INVOICE

51348

DATE

4-5-22



PATIENT

Otis Robertson

SPECIES

Feline

BREED

DLH

SEX

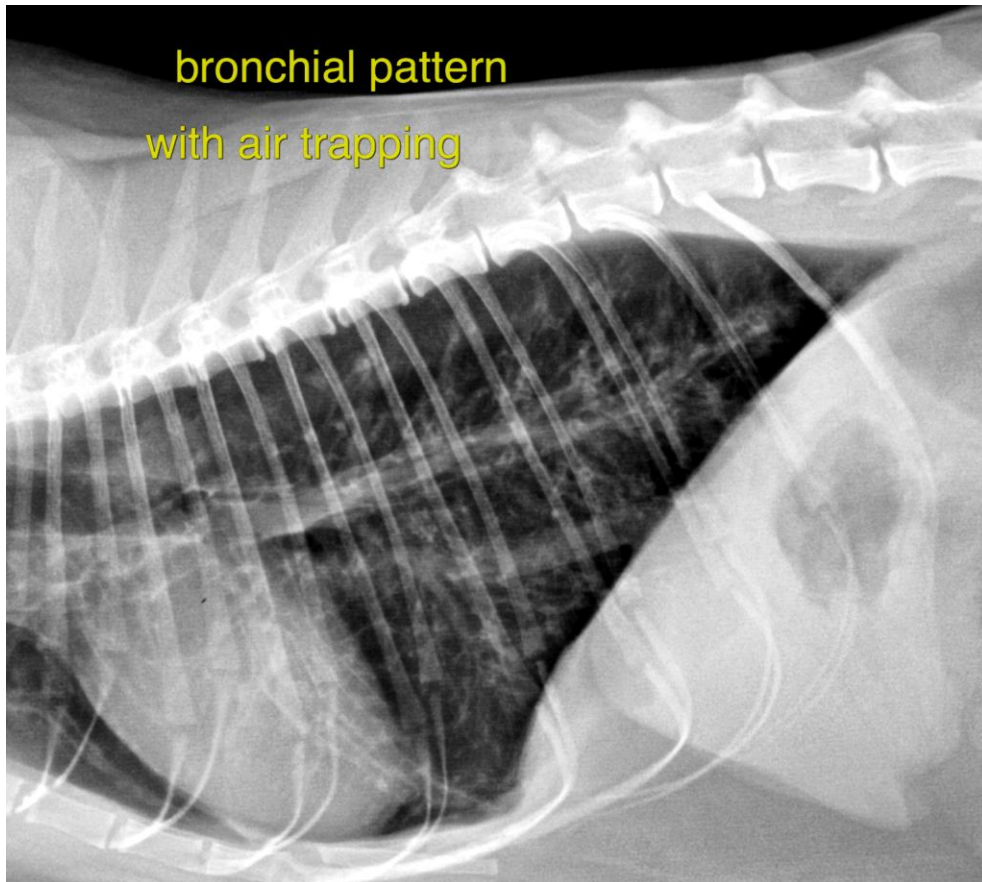
Male Neuter

AGE

3 Years

INTERPRETED BY

Nele Eley, DVM
Dr. med. Vet. DipECVDI



HOSPITAL NAME

St. Catherine's Animal
Hospital

REFERRING VET

Dr. Boctor

INVOICE

51348

DATE

4-5-22

The information and recommendations provided are based on the images presented by the referring veterinarian/sonographer. No evaluation can be communicated regarding pathology that was not visible in the image/video clips provided.

Thank you for this referral. If the clinical or image interpretation does not parallel your findings or if I can be of any further assistance please contact me.

Nele Eley, DVM, Dr. med. vet., DipECVDI
European Specialist in Veterinary Diagnostic Imaging, Cert. Radiology,
Senior lecturer University of Giessen, Germany, Veterinary Faculty, Department of Radiology
Nele.Eley@sonopath.com