


PATIENT PRESENTING CLINICAL SIGNS

Nugget Aiello Two days ago (Sunday) had diarrhea, no blood. Vomiting a lot over the last 24 hours. Unknown if foreign body ingestion.

SPECIES RADIOGRAPHIC STUDY OF THE ABDOMEN

Canine Lateral and ventrodorsal views provided for review, totaling two images.

RADIOGRAPHIC FINDINGS

BREED The abdominal serosal detail is maintained.

Dachshund The gastrointestinal tract is largely empty. A mild amount of gas is seen within the stomach. There is no evidence of abnormal dilation, displacement or foreign material of or within the stomach. The ascending, transverse and descending colon are filled with gas. A segmental gas pattern is seen within the small intestine. No overt dilation, plication or radiopaque foreign material is noted. However, the gas-filled loops are turgid in appearance.

SEX

Spayed Female

RADIOGRAPHIC DIAGNOSIS
AGE

- Gastrointestinal maldigestion pattern with no definitive signs of mechanical ileus

2 Years

INTERPRETATION OF FINDINGS & FURTHER RECOMMENDATIONS
INTERPRETED BY

Nele Eley (Ondreka),
 DVM Dr. med. vet.,
 DipECVDI

The radiographic findings of the gastrointestinal tract are unspecific. No definitive signs of mechanical obstruction are seen. The findings are more suggestive for functional rather than mechanical history. However, subileus cannot be ruled out entirely. Consider recheck radiographs or abdominal ultrasound for further definition, should the patient's clinical signs have persisted.

HOSPITAL NAME

Four Corners VC

REFERRING VET

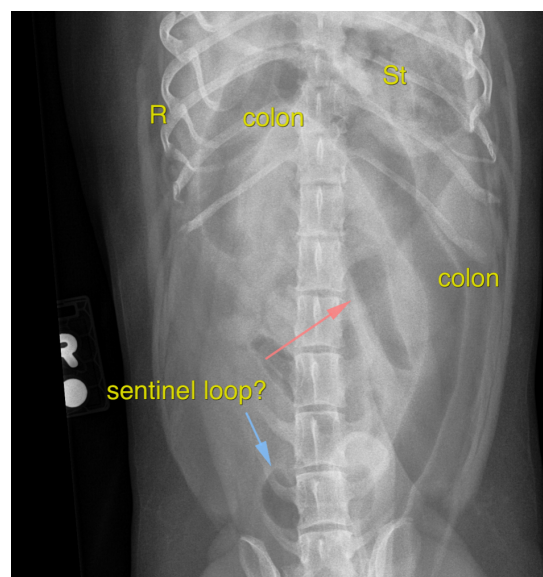
Dr. Melina Maritato

INVOICE

36764

DATE

4/5/22





PATIENT

The information and recommendations provided are based on the images presented by the referring veterinarian. No evaluation can be communicated regarding pathology that was not visible in the image/video clips provided.

Nugget Aiello

SPECIES

Canine

Thank you for this referral. If the clinical or image interpretation does not parallel your findings or if I can be of any further assistance please contact me.

BREED

Dachshund

Nele Eley (Ondreka), DVM, Dr. med. vet., DipECVDI
European Specialist in Veterinary Diagnostic Imaging, Cert. Radiology,
Senior lecturer University of Giessen/Germany, Veterinary Faculty, Department of Radiology.
Nele.Eley@sonopath.com

SEX

Spayed Female

AGE

2 Years

INTERPRETED BY

Nele Eley (Ondreka),
DVM Dr. med. vet.,
DipECVDI

HOSPITAL NAME

Four Corners VC

REFERRING VET

Dr. Melina Maritato

INVOICE

36764

DATE

4/5/22