



PATIENT

Mister Barber

SPECIES

Feline

BREED

DSH

SEX

MN

AGE

4 Years

INTERPRETED BY

Nele Eley, DVM
Dr. med. Vet. DipECVDI

HOSPITAL NAME

Mountain West
Veterinary Hospital

REFERRING VET

Dr. Jeff Simmons

INVOICE

57624

DATE

4-4-23

PRESENTING CLINICAL SIGNS

P presented for respiratory distress. No previous history of respiratory distress. Radiographs showed mild asthma and a significant tracheal collapse. Bronchoscope showed a 2-3 tracheal collapse in a feline patient. Confirming to make sure a stent is needed since the P is not able to be out of oxygen.

Abnormal PE/Chem/CBC/UA Results: Trachea narrowing and on CT suspect atelectasis.

COMPUTED TOMOGRAPHIC STUDY OF THE NECK & THORAX

Plain and post contrast studies available for review.

COMPUTED TOMOGRAPHIC FINDINGS

Dorsal flattening of the cervical trachea appears to be present starting immediately caudal to the larynx. The tracheal lumen appears to be kept open by the endotracheal tube and its cuff which is positioned level with the thoracic inlet. The intrathoracic trachea presents within normal limits.

Mild atelectatic changes of the lung accentuating the right middle lobe are seen. The remainder of the lung presents within normal limits.

No structural abnormality of the larynx is seen.

The cardiovascular structures present within normal limits.

The mediastinal lymph nodes present within normal limits.

COMPUTED TOMOGRAPHIC DIAGNOSIS

- Suspect dynamic tracheal disease of the cervical trachea.
- Normal bronchopulmonary structures except for mild atelectasis.

INTERPRETATION OF THE FINDINGS & FURTHER RECOMMENDATIONS

The assessment of the trachea is limited due to the presence of endotracheal tubing which seems to be a necessity in this patient. The dorsal flattening and the fact that the lumen of the cervical trachea appears to be held open by the tracheal tube, however, support the clinical suspicion of dynamic tracheal disease of the cervical trachea.



PATIENT

Mister Barber

SPECIES

Feline

BREED

DSH

SEX

MN

AGE

4 Years

INTERPRETED BY

Nele Eley, DVM
Dr. med. Vet. DipECVDI

HOSPITAL NAME

Mountain West
Veterinary Hospital

REFERRING VET

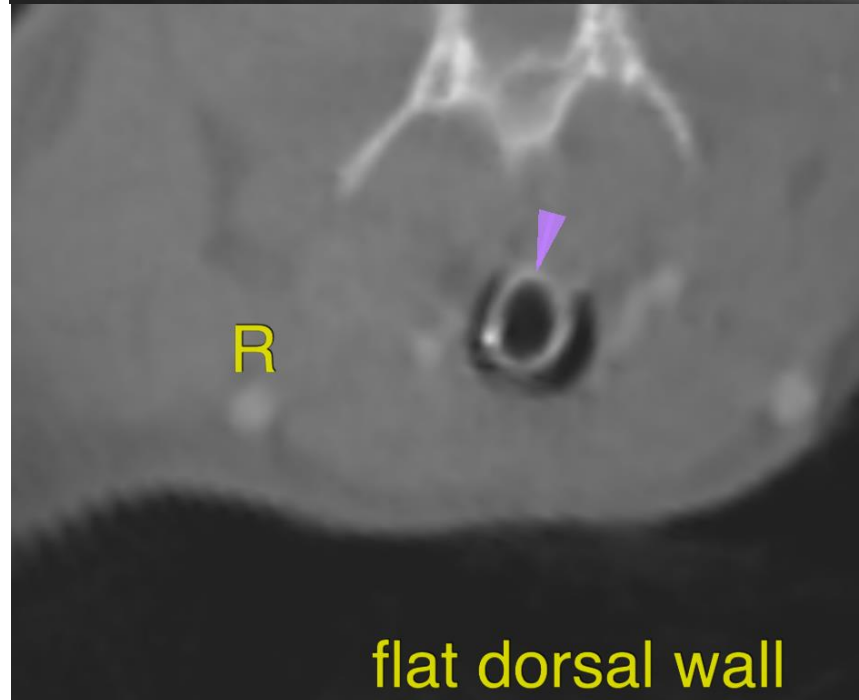
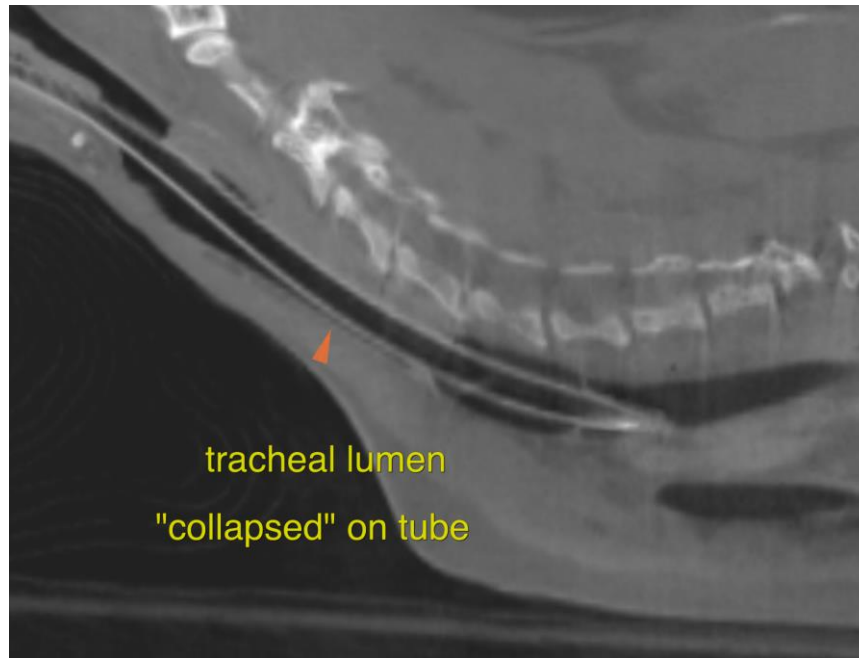
Dr. Jeff Simmons

INVOICE

57624

DATE

4-4-23





PATIENT

Mister Barber

The information and recommendations provided are based on the images presented by the referring veterinarian/sonographer. No evaluation can be communicated regarding pathology that was not visible in the image/video clips provided.

Thank you for this referral. If the clinical or image interpretation does not parallel your findings or if I can be of any further assistance please contact me.

SPECIES

Feline

Nele Eley, DVM, Dr. med. vet., DipECVDI
European Specialist in Veterinary Diagnostic Imaging, Cert. Radiology,
Senior lecturer University of Giessen, Germany, Veterinary Faculty, Department of Radiology
Nele.Eley@sonopath.com

BREED

DSH

SEX

MN

AGE

4 Years

INTERPRETED BY

Nele Eley, DVM
Dr. med. Vet. DipECVDI

HOSPITAL NAME

Mountain West
Veterinary Hospital

REFERRING VET

Dr. Jeff Simmons

INVOICE

57624

DATE

4-4-23