



PATIENT

Lily #31908A Pettit
Red Barn Veterinary
Clinic

SPECIES

Canine

BREED

German Shorthair

SEX

F

AGE

11 Months

INTERPRETED BY

Nele Eley, DVM
Dr. med. Vet. DipECVDI

HOSPITAL NAME

Gentle Doctor Animal
Hospital

REFERRING VET

Pete Bashara, DVM

INVOICE

57616

DATE

4-4-23

PRESENTING CLINICAL SIGNS

Owner reports normal gait when in motion but at rest - standing - stands on the tops of the hind feet -- no overt signs of pain - no improvement with NSAID trial but owner reports symptoms more evident with exercise/activity. Imaging today as ortho referred to neuro and neuro referred to ortho. Owner understands screening CT and IV contrast - not myelogram.
Abnormal PE/Chem/CBC/UA Results: No changes in labs from RDVM --

COMPUTED TOMOGRAPHIC STUDY OF THE LUMBAR SPINE

Plain and post IV contrast studies of the lumbar spine and lumbosacral junction available for review.

COMPUTED TOMOGRAPHIC FINDINGS

Number, alignment, and general anatomy of the lumbar vertebrae present within normal limits. There is no evidence of disc herniation, discospondylitis, traumatic osseous injury, or congenital malformation.

The lumbosacral junction presents within normal limits.

Both coxofemoral joints are seen and present within normal limits as well.

The uterus is mildly prominent with no evidence of fluid content.

A small amount of gas is seen in the subcutis of the left flank and likely iatrogenic.

COMPUTED TOMOGRAPHIC DIAGNOSIS

- Normal CT presentation of the lumbar spine, lumbosacral junction, and coxofemoral joints.

INTERPRETATION OF THE FINDINGS & FURTHER RECOMMENDATIONS

The CT study revealed no evidence of structural abnormality within the lumbar spine, lumbosacral junction, or coxofemoral joints. Inflammatory/infectious, neuromuscular, vascular, and other pathology cannot be ruled out entirely and further definition by means of a CT myelogram or an MRI as well as csf analysis could be considered in case of persisting or deteriorating clinical signs.

The prominence of the uterus is likely female cycle dependent and within normal limits.



PATIENT

Lily #31908A Pettit
Red Barn Veterinary
Clinic

SPECIES

Canine

BREED

German Shorthair

SEX

F

AGE

11 Months

INTERPRETED BY

Nele Eley, DVM
Dr. med. Vet. DipECVDI

HOSPITAL NAME

Gentle Doctor Animal
Hospital

REFERRING VET

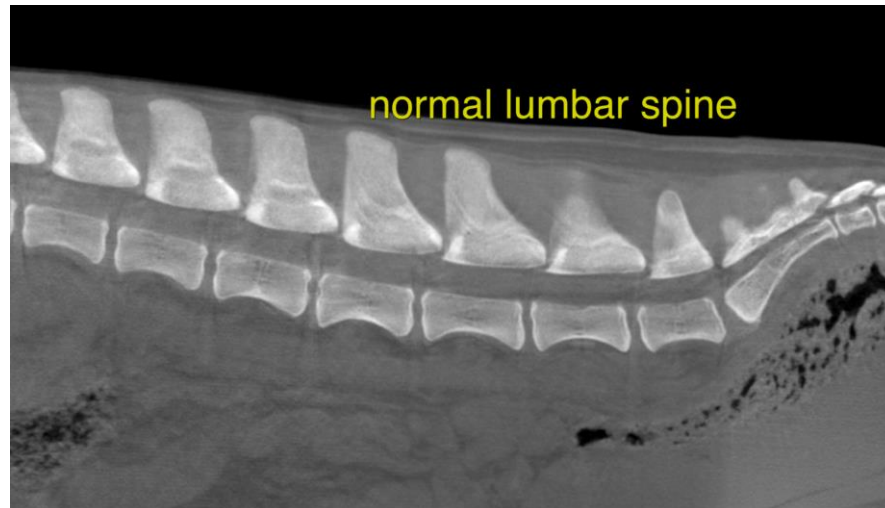
Pete Bashara, DVM

INVOICE

57616

DATE

4-4-23



The information and recommendations provided are based on the images presented by the referring veterinarian/sonographer. No evaluation can be communicated regarding pathology that was not visible in the image/video clips provided.

Thank you for this referral. If the clinical or image interpretation does not parallel your findings or if I can be of any further assistance please contact me.

Nele Eley, DVM, Dr. med. vet., DipECVDI
European Specialist in Veterinary Diagnostic Imaging, Cert. Radiology,
Senior lecturer University of Giessen, Germany, Veterinary Faculty, Department of Radiology
Nele.Eley@sonopath.com