



**PATIENT**

Pepperoni Tony Miko

**PRESENTING CLINICAL SIGNS**

Patient started having a swelling between eyes in January that has progressed. rDVM worked it up some. It was negative for fungal serology. Patient has been on antibiotics and anti-inflammatories and is currently on prednisolone.

**SPECIES**

Feline

Abnormal PE/Chem/CBC/UA Results: Mild leukocytosis 21,500 with neutrophilia 18,160 and monocytosis 890; organ chemistries are WNL

**COMPUTED TOMOGRAPHIC STUDY OF THE HEAD**

**BREED**

DSH

Post contrast study available for review.

**SEX**

MN

**AGE**

9

**COMPUTED TOMOGRAPHIC FINDINGS**

A large irregular shaped and ill-defined soft tissue attenuating mass with strong nonuniform contrast enhancement is seen within the right nasal cavity. The mass measures approximately 4 cm in length, 3.5 cm in height, and 3.5 cm in width. The lesion margins are ill-defined. Polyostotic aggressive bone lysis of the right and left nasal bones, right frontal bone, right bony orbita, right maxilla, nasal septum, and cribriform plate are seen. The mass occupies the entire nasal fundus and causes airway obstruction. A large part of the mass extends onto the dorsum of the nose and into the right orbita. Severe compression of the right eye is seen with severe temporal nasal deformity of the ocular globe, posterior luxation of the lens, and increased enhancement and thickening of the choroidea. The mass extends into the cranial vault. An extraaxial mass effect onto the bilateral olfactory bulbs and frontal lobes, R>L, is noted.

**INTERPRETED BY**

Nele Eley, DVM  
Dr. med. Vet. DipECVDI

The right tympanic bulla contains a mild amount of fluid attenuating material.

The submandibular and medial retropharyngeal lymph nodes present within normal limits.

**COMPUTED TOMOGRAPHIC DIAGNOSIS**

**HOSPITAL NAME**

Petroglyph Animal Hospital

- Soft tissue mass with aggressive biological behavior within the right nasal cavity with extension into the left nasal cavity, right orbita, onto the dorsum of the nose, into the nasal fundus, and into the cranial vault with extraaxial mass effect onto the brain and severe compression and distortion of the right eye.
- Mild right sided otitis media.
- No evidence of lymph node metastases.

**REFERRING VET**

Alice Ku

**INTERPRETATION OF THE FINDINGS & FURTHER RECOMMENDATIONS**

**INVOICE**

58047

The CT findings are compatible with a malignant soft tissue neoplasia within the right nasal cavity with extension into the left nasal cavity, nasal fundus, right orbita, onto the dorsum of the nose, and into the cranial vault. Differential diagnosis includes nasal adenocarcinoma, other carcinoma, lymphosarcoma, and fibrosarcoma. Final diagnosis would require sampling for histology. The extensive tumor growth with intracranial extension and compression and distortion of the right eye should be considered, however.

**DATE**

4-30-23



**PATIENT**

Pepperoni Tony Miko

**SPECIES**

Feline

**BREED**

DSH

**SEX**

MN

**AGE**

9

**INTERPRETED BY**

Nele Eley, DVM  
Dr. med. Vet. DipECVDI

**HOSPITAL NAME**

Petroglyph Animal  
Hospital

**REFERRING VET**

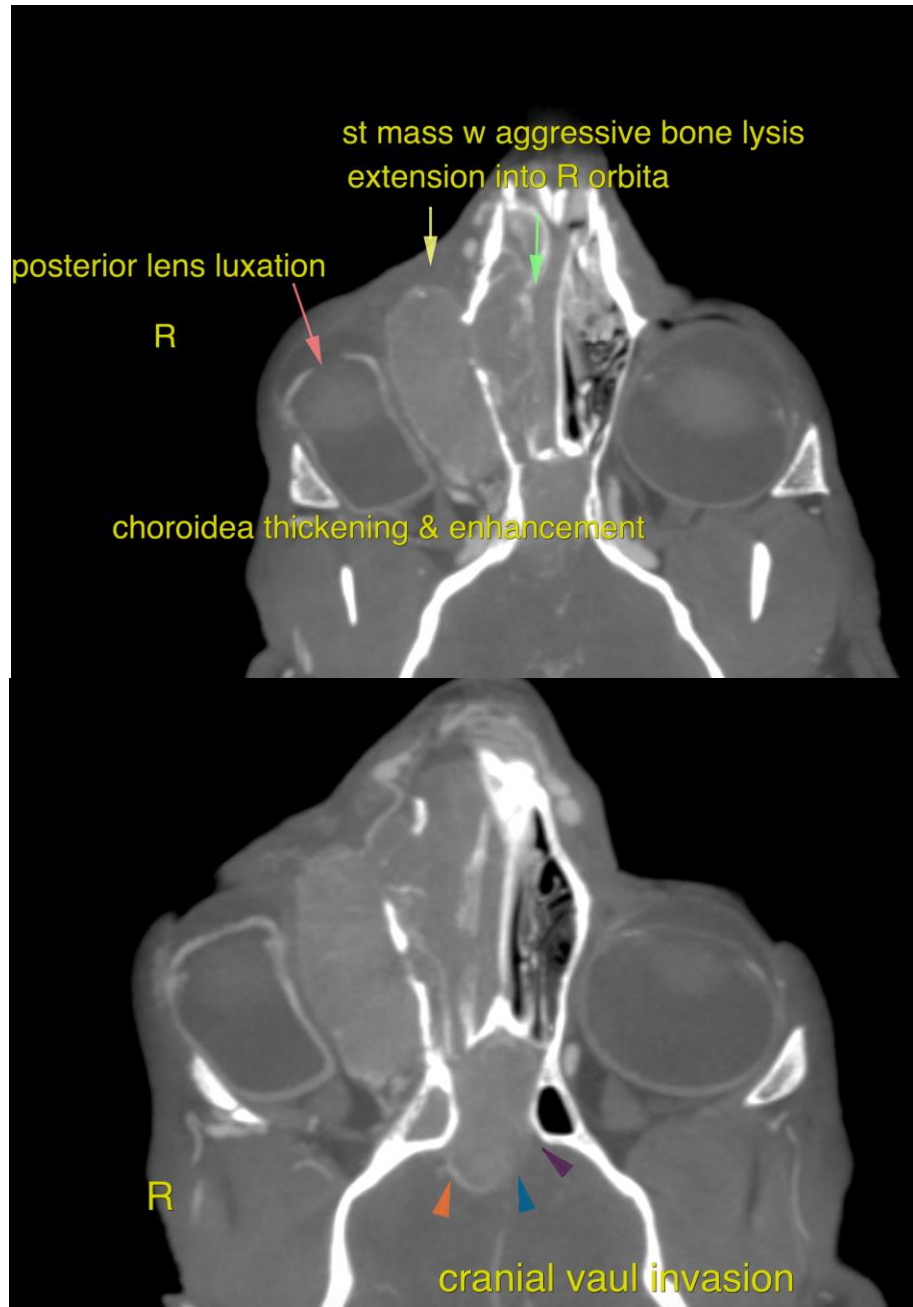
Alice Ku

**INVOICE**

58047

**DATE**

4-30-23





**PATIENT**

Pepperoni Tony Miko

The information and recommendations provided are based on the images presented by the referring veterinarian/sonographer. No evaluation can be communicated regarding pathology that was not visible in the image/video clips provided.

**SPECIES**

Feline

Thank you for this referral. If the clinical or image interpretation does not parallel your findings or if I can be of any further assistance please contact me.

**BREED**

DSH

**Nele Eley**, DVM, Dr. med. vet., DipECVDI  
European Specialist in Veterinary Diagnostic Imaging, Cert. Radiology,  
Senior lecturer University of Giessen, Germany, Veterinary Faculty, Department of Radiology  
Nele.Eley@sonopath.com

**SEX**

MN

**AGE**

9

**INTERPRETED BY**

Nele Eley, DVM  
Dr. med. Vet. DipECVDI

**HOSPITAL NAME**

Petroglyph Animal  
Hospital

**REFERRING VET**

Alice Ku

**INVOICE**

58047

**DATE**

4-30-23