

**PATIENT**

Diesel Helinski

PRESENTING CLINICAL SIGNS

Limping on back left leg for 2-3 months, had ACL Sx in the fall

SPECIES

Canine

ULTRASONOGRAPHIC FINDINGS**Left Stifle**

Left stifle has a history of cranial cruciate ligament injury and surgery last fall.

BREED

Shepherd Mix

Moderate amount of anechoic effusion is present within the supra- and infra- patellar recesses of the left stifle joint. Moderate thickening of the synovium is seen. The medial collateral ligament is thickened.

SEX

Male Neutered

The caudal horn of the medial meniscus is partially seen. Internal heterogeneity of the caudal horn of the medial meniscus is seen accentuating its proximal surface.

The cranial cruciate ligament is represented by discontinuous smoothly delineated hyperechoic fibers at the intercondylar eminence of the tibia. Fat pad heterogeneity is noted.

AGE

7 Years

No abnormality of the lateral meniscus is detected.

ULTRASONOGRAPHIC DIAGNOSIS

- Moderate chronic left stifle osteoarthritis with cranial cruciate ligament injury and suspect medial meniscopathy.

INTERPRETED BYNele Eley, DVM
Dr. med. Vet. DipECVDI**INTERPRETATION OF THE FINDINGS & FURTHER RECOMMENDATIONS**

The ultrasonographic findings suggest presence of medial meniscus injury localized to the caudal horn. Further workup by means of arthroscopy could be considered in case of persisting lameness.

HOSPITAL NAME

SVS Imaging CT

REFERRING VETAdvanced Animal
Hospital- Dr. Dolan**INVOICE**

51831

DATE

4-30-22



PATIENT

Diesel Helinski

SPECIES

Canine

BREED

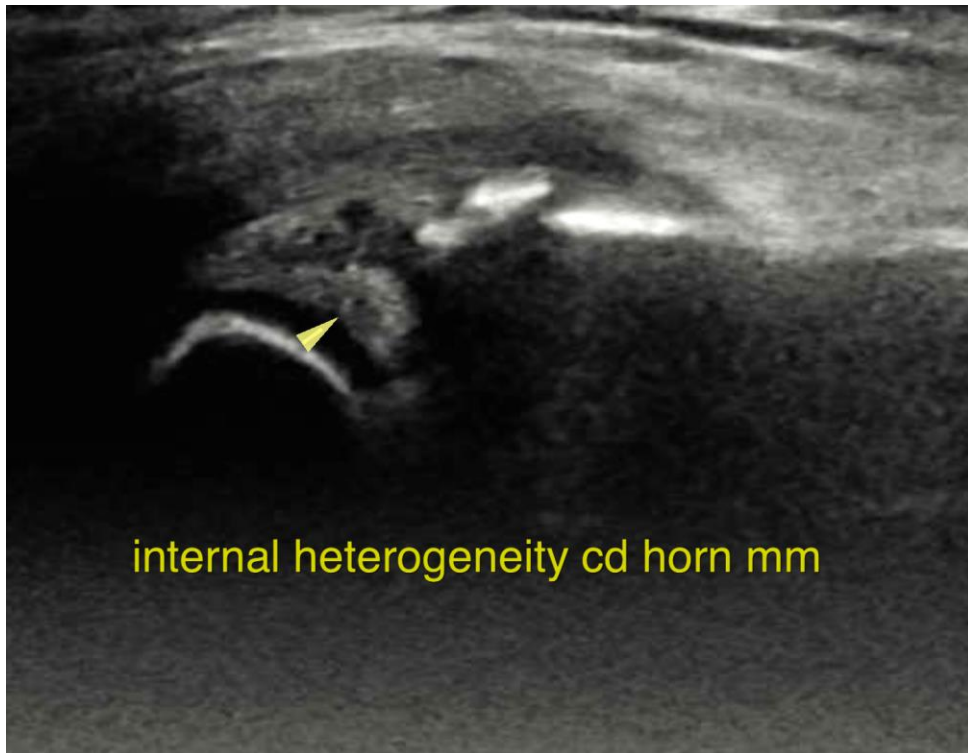
Shepherd Mix

SEX

Male Neutered

AGE

7 Years



INTERPRETED BY

Nele Eley, DVM
Dr. med. Vet. DipECVDI

HOSPITAL NAME

SVS Imaging CT

REFERRING VET

Advanced Animal
Hospital- Dr. Dolan

INVOICE

51831

DATE

4-30-22

The information and recommendations provided are based on the images presented by the referring veterinarian/sonographer. No evaluation can be communicated regarding pathology that was not visible in the image/video clips provided.

Thank you for this referral. If the clinical or image interpretation does not parallel your findings or if I can be of any further assistance please contact me.

Nele Eley, DVM, Dr. med. vet., DipECVDI
European Specialist in Veterinary Diagnostic Imaging, Cert. Radiology,
Senior lecturer University of Giessen, Germany, Veterinary Faculty, Department of Radiology
Nele.Eley@sonopath.com