



PATIENT

Gracie Cindrich

PRESENTING CLINICAL SIGNS

Pet presented for a dental cleaning with extraction of upper left canine.

SPECIES

Canine

COMPUTED TOMOGRAPHIC STUDY OF THE DENTAL ARCADES

Flat panel CT study of the dental arcades available for review.

BREED

Pitbull

COMPUTED TOMOGRAPHIC FINDINGS

Mild widening of the periodontal spaces of the triadans 101 and 102 is seen.

SEX

FS

There is moderate periodontal space widening of the triadan 201.

Mild apical periodontal space widening of the triadan 202 is seen.

AGE

8 Years

All of the tooth crown of the triadan 204 is absent. A root remnant with severely widened pulp cavum and resorptive lesions of the dental cementum and enamel is seen. The periodontal space widening is apical and only mild here.

Moderate periodontal space widening of the triadan 205 is noted.

INTERPRETED BY

Nele Eley, DVM
Dr. med. Vet. DipECVDI

A root remnant of the triadan 305 is seen.

Severe CORL lesions of the triadan 406 dental crown and root are noted with moderate periodontal space widening.

HOSPITAL NAME

Cranberry Holistic
Pet Care

COMPUTED TOMOGRAPHIC DIAGNOSIS

- Severe complicated crown fracture and chronic pulpitis with resorptive lesions of the triadan 204.
- Root fragmentation and periodontitis of the triadan 109.
- Severe CORL and moderate periodontitis of the triadan 406.
- Mild to moderate periodontitis of the triadans 101, 102, 201, 202, 205.
- Root remnant triadan 305.

REFERRING VET

Cynthia Maro

INTERPRETATION OF THE FINDINGS & FURTHER RECOMMENDATIONS

The CT study reveals severe complicated crown fracture, chronic pulpitis, and resorptive lesions of the triadan 204 with mild apical periodontitis as well as fragmentation and moderate periodontitis of the triadan 109 and severe CORL of the triadan 306. Dental extraction of the aforementioned teeth are indicated.

INVOICE

57584

DATE

4-3-23

Mild to moderate periodontitis is also noted for the triadans 101, 102, 201, 202, and 205. Clinical correlation required in order to determine the need for extractions of the aforementioned dental elements.



PATIENT

Gracie Cindrich

SPECIES

Canine

BREED

Pitbull

SEX

FS

AGE

8 Years

INTERPRETED BY

Nele Eley, DVM
Dr. med. Vet. DipECVDI

HOSPITAL NAME

Cranberry Holistic
Pet Care

REFERRING VET

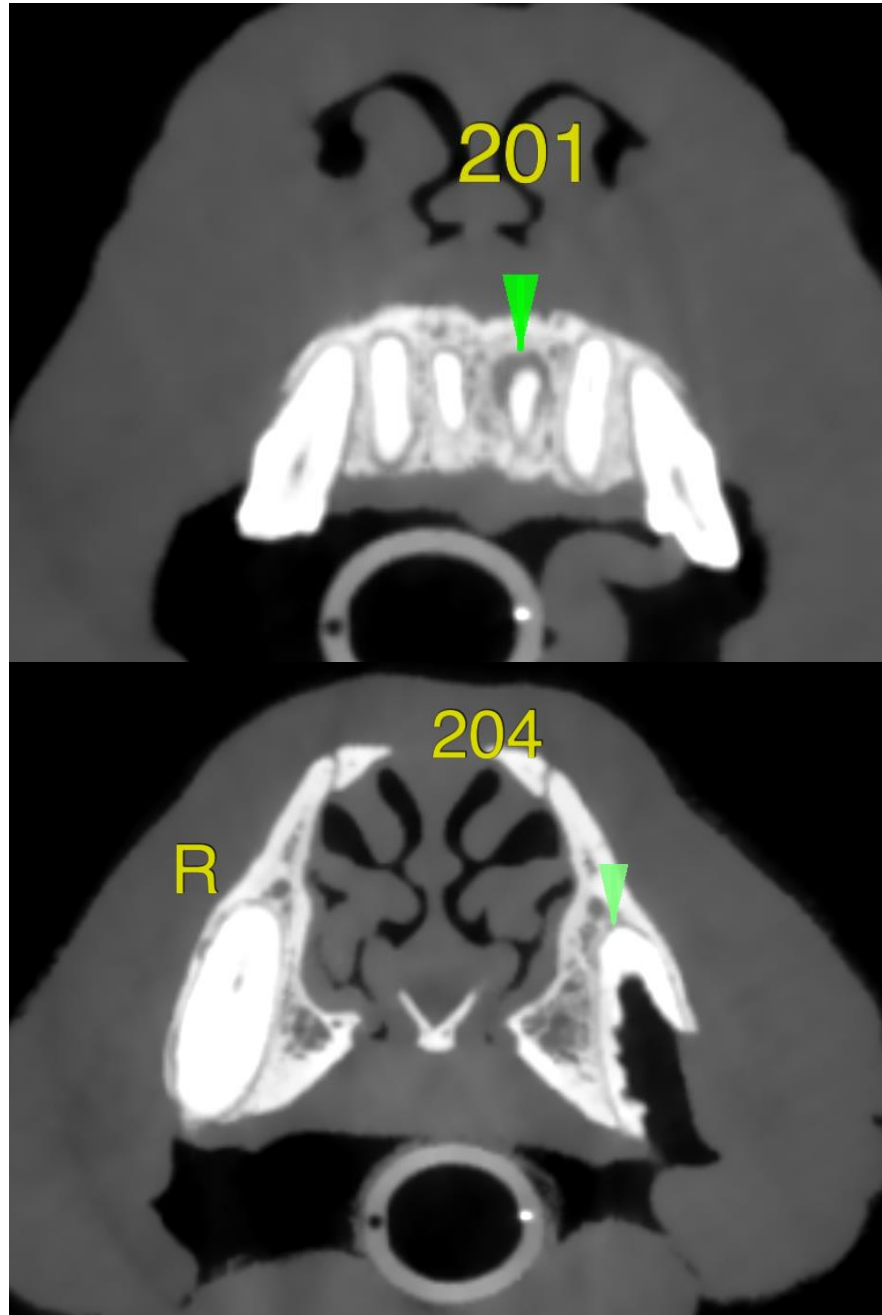
Cynthia Maro

INVOICE

57584

DATE

4-3-23





PATIENT

Gracie Cindrich

SPECIES

Canine

BREED

Pitbull

SEX

FS

AGE

8 Years

INTERPRETED BY

Nele Eley, DVM
Dr. med. Vet. DipECVDI

HOSPITAL NAME

Cranberry Holistic
Pet Care

REFERRING VET

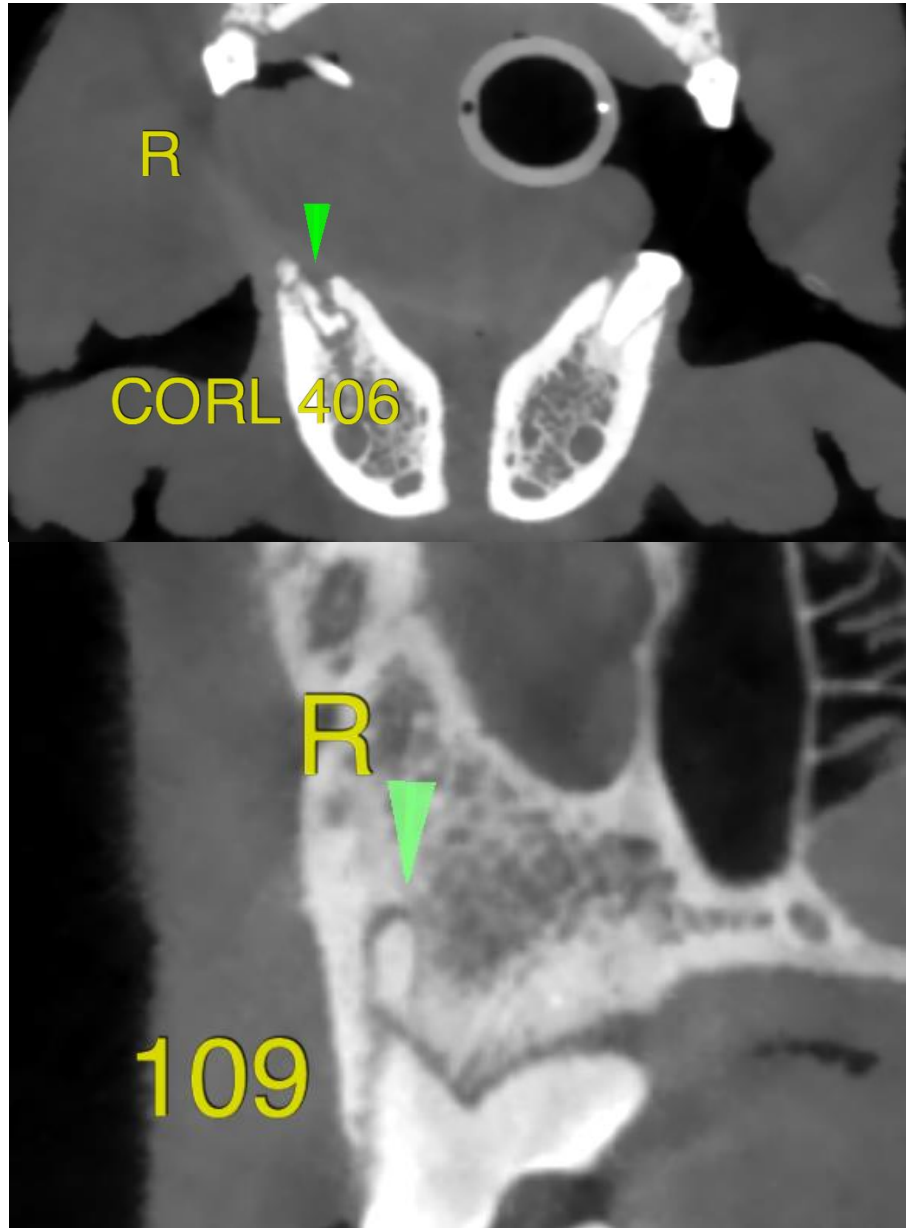
Cynthia Maro

INVOICE

57584

DATE

4-3-23





PATIENT

Gracie Cindrich

The information and recommendations provided are based on the images presented by the referring veterinarian/sonographer. No evaluation can be communicated regarding pathology that was not visible in the image/video clips provided.

SPECIES

Canine

Thank you for this referral. If the clinical or image interpretation does not parallel your findings or if I can be of any further assistance please contact me.

BREED

Pitbull

Nele Eley, DVM, Dr. med. vet., DipECVDI
European Specialist in Veterinary Diagnostic Imaging, Cert. Radiology,
Senior lecturer University of Giessen, Germany, Veterinary Faculty, Department of Radiology
Nele.Eley@sonopath.com

SEX

FS

AGE

8 Years

INTERPRETED BY

Nele Eley, DVM
Dr. med. Vet. DipECVDI

HOSPITAL NAME

Cranberry Holistic
Pet Care

REFERRING VET

Cynthia Maro

INVOICE

57584

DATE

4-3-23