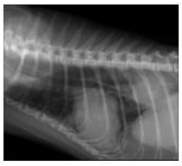
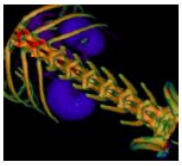
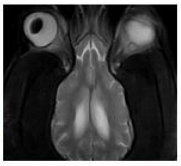

PATIENT

Big Boy Hew

SPECIES

Canine

BREED

Bulldog Mix

SEX

Neutered Male

AGE

11 Years

INTERPRETED BY

Nele Eley (Ondreka), DVM Dr. med. vet., DipECVDI

HOSPITAL NAME

Mobile Pet Imaging

REFERRING VET

Meaux

INVOICE

51832

DATE

4-29-22

PRESENTING CLINICAL SIGNS

*DVM pet. Mass cranial to Right kidney, right adrenal not seen on ultrasound. Previous CT due to nasal discharge (refer to attached report). Now the nasal discharge is occasional and only noted from the Right nostril. Previous Hx of 2 exploratory surgeries due to foreign bodies.
Abnormal PE/Chem/CBC/UA Results: *DVM pet. Abdominal ultrasound report attached.

COMPUTED TOMOGRAPHIC STUDY OF THE HEAD, THORAX, & ABDOMEN

Plain and post contrast studies of the head and abdomen and post contrast study only of the thorax available for review.

Findings of the head compared to the prior report dated 2-18-21.

COMPUTED TOMOGRAPHIC FINDINGS

Head

The brain presents no deviation from normal anatomy and symmetry. The grey and white matter distinction and the neuroparenchymal attenuation are as expected. The distribution of contrast enhancement is within normal limits throughout the parenchyma and meninges. The ventricular system is non-dilated and within the limits of the expected volume and symmetry.

A minimal amount of fluid attenuating material is seen within the right naris. Mild bilateral swelling of the mucosal lining of the nasal turbinates is seen within the rostral third of both nasal cavities. Mild focal paucity/atrophy of the turbinates is noted in the mid third of the right nasal cavity.

Both temporomandibular joints present congruent joint spaces with even subchondral bone surfaces and are considered within normal limits.

Thickening of the epithelial lining of both external auditory meatuses as well as osseous wall metaplasia of the horizontal part of the external auditory meatuses is seen. Both tympanic bullae are aerated, the mucosal lining is not seen, the bony wall is smooth and thin.

The submandibular and medial retropharyngeal lymph nodes are small and elongated with a normal short-to-long-axis-ratio is < 0.5, the attenuation and contrast enhancement pattern is uniform.

The salivary glands present within normal limits.

The triadans 308 and 408 are absent. Horizontal abrasion of the triadans 104 and 204 is seen.

The findings of the soft palate and epiglottis are stationary.

Thorax

The bony and surrounding soft tissue structures are within normal limits.

The sternal, cranial mediastinal and tracheobronchial lymph nodes are small elongated with a normal short-to-long-axis-ratio is < 0.5, the attenuation and contrast enhancement pattern are uniform and considered within normal limits.

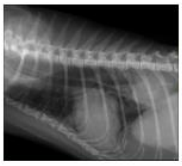
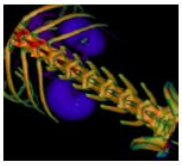
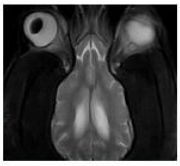

PATIENT

Big Boy Hew

SPECIES

Canine

BREED

Bulldog Mix

SEX

Neutered Male

AGE

11 Years

INTERPRETED BY

Nele Eley (Ondreka), DVM Dr. med. vet., DipECVDI

HOSPITAL NAME

Mobile Pet Imaging

REFERRING VET

Meaux

INVOICE

51832

DATE

4-29-22

The cardiovascular structures including the pulmonary vasculature are within normal limits.

Mild generalized bronchial wall enhancement is noted and considered within age related limits.

The lung parenchyma presents the expected architecture and attenuation behavior.

Small incidental gas pockets are seen within the esophageal lumen, there is no evidence of abnormal dilation.

Abdomen

An 8 x 6 x 5 cm sized irregular shaped mass with lobulated appearance and soft tissue attenuation is seen in the right cranial and dorsal abdomen cranial to the right kidney. Direct contact between the mass and cranial pole of the right kidney is noted. The cranial pole of the right kidney presents focal concavity level with the contact zone. Moderate heterogeneous contrast enhancement is noted on the post-contrast study within the mass. The mass is lateral to the right adrenal gland and no direct emergence from the right adrenal gland can be seen.

The right adrenal gland presents within normal limits in terms of its shape, size, and attenuation. The left adrenal gland presents within normal limits.

The corticomedullary definition of both kidneys is indistinct. A minimal amount of mineral attenuating material is present within the renal diverticuli of both kidneys. Mild surface irregularity of the kidneys is noted and the nephrogram is slightly weak and heterogeneous on both sides.

Both liver and spleen present with normal shape, even surface, uniformly attenuating parenchyma and homogeneous contrast enhancement, unremarkable.

The pancreas is evenly contoured, the pancreatic parenchyma is homogeneous and presents uniform contrast enhancement.

The position, delineation, wall and content of the gastrointestinal tract are considered within normal limits throughout.

Moderate degenerative lumbosacral stenosis with moderate protrusion of the intervertebral disc and extensive remodeling of the vertebral end plates as well as spondylosis deformans is seen.

COMPUTED TOMOGRAPHIC DIAGNOSIS

- Soft tissue mass meeting neoplastic criteria in the right cranial abdomen with direct contact to the cranial pole of the right kidney.
- Bilateral chronic nephropathy pattern.
- Moderate degenerative lumbosacral stenosis.
- Mild bilateral rhinitis - right more than left.
- Chronic bilateral otitis externa.
- Thick soft palate.

PATIENT

Big Boy Hew

SPECIES

Canine

BREED

Bulldog Mix

SEX

Neutered Male

AGE

11 Years

INTERPRETED BY

Nele Eley (Ondreka), DVM Dr. med. vet., DipECVDI

HOSPITAL NAME

Mobile Pet Imaging

REFERRING VET

Meaux

INVOICE

51832

DATE

4-29-22

INTERPRETATION OF FINDINGS & FURTHER RECOMMENDATIONS

The CT study reveals a large soft tissue mass with evidence of aggressive biological behavior in the right cranial abdomen. The mass is in direct contact with the cranial pole of the right kidney and right renal origin is one potential. The right adrenal gland presents within normal limits in terms of its size and shape and origin from the right adrenal gland is considered unlikely. Consider soft tissue carcinoma, sarcoma, and less likely round cell neoplasia with potential emergence from 1, the right kidney; two, general abdomen; or three, right adrenal gland. No evidence of vascular invasion such as the caudal vena cava is seen at this point. Consider surgical exploration with potential nephrectomy of the right kidney.

At this time, there was no evidence of regional metastatic disease to the lymph nodes or distant metastatic disease to the lung.

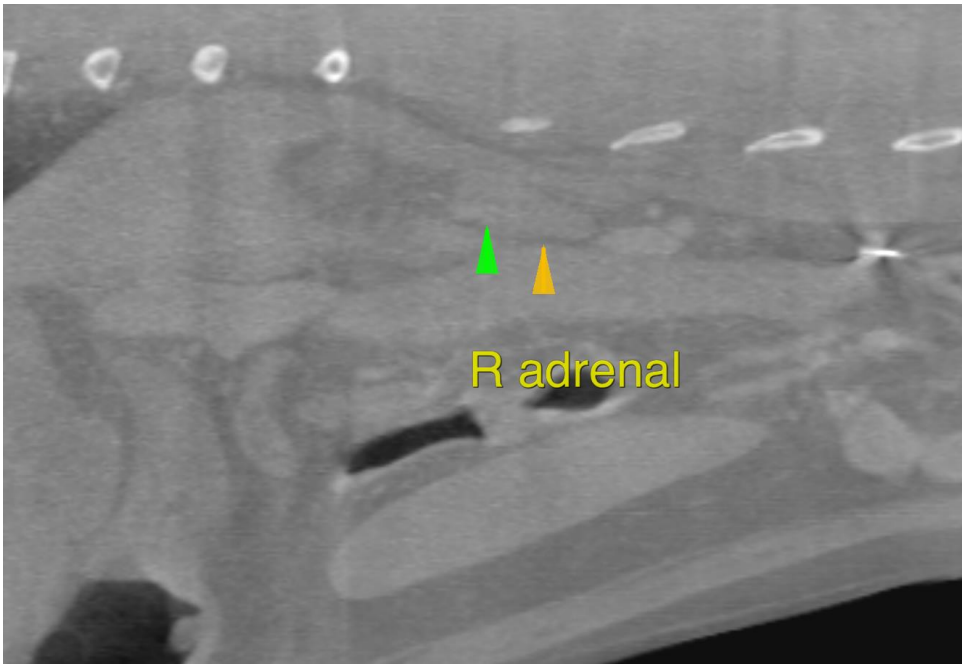

SonoPath Teleradiology

MOBILE PET IMAGING®
VETERINARY CT SCANS & FLUOROSCOPIES

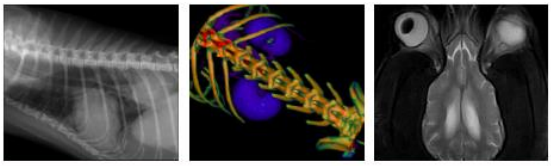

EDUCATIONAL TELECONSULTATION SERVICES™

SonoPath.com
1-800-838-4268 info@sonopath.com

PATIENT

Big Boy Hew

SPECIES

Canine

BREED

Bulldog Mix

SEX

Neutered Male

AGE

11 Years

INTERPRETED BY

Nele Eley (Ondreka), DVM Dr. med. vet., DipECVDI

HOSPITAL NAME

Mobile Pet Imaging

REFERRING VET

Meaux

INVOICE

51832

DATE

4-29-22

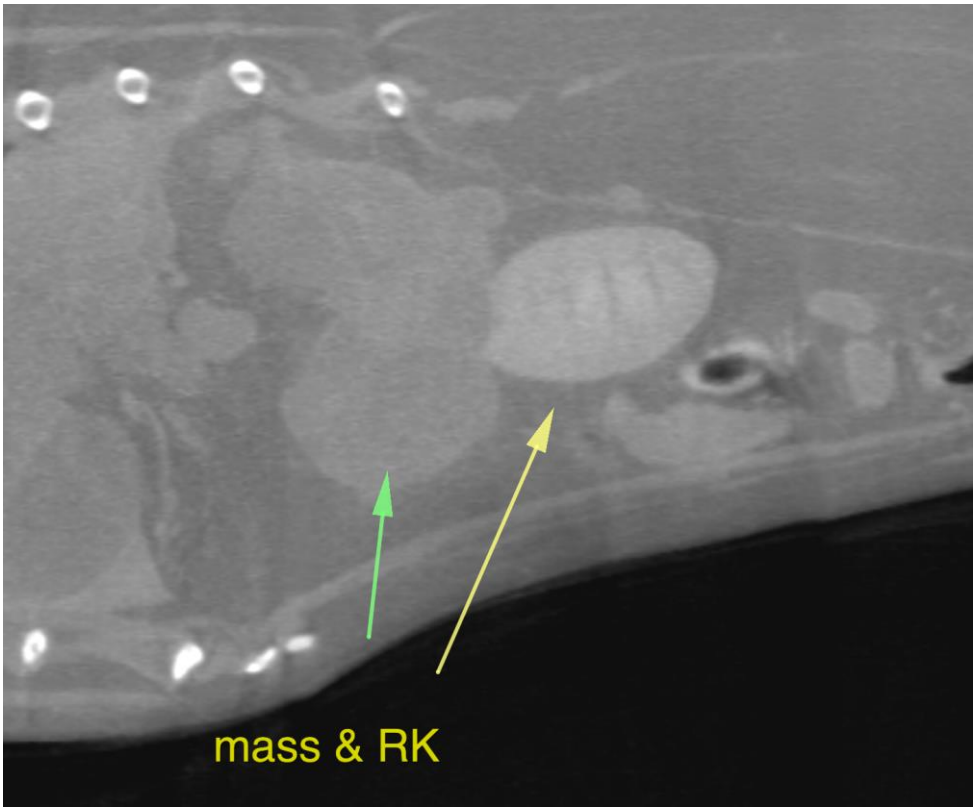

The information and recommendations provided are based on the images presented by the referring veterinarian. No evaluation can be communicated regarding pathology that was not visible in the image/video clips provided.

Thank you for this referral. If the clinical or image interpretation does not parallel your findings or if I can be of any further assistance please contact me.

Nele Eley (Ondreka), DVM, Dr. med. vet., DipECVDI
European Specialist in Veterinary Diagnostic Imaging, Cert. Radiology,
Senior lecturer University of Giessen/Germany, Veterinary Faculty, Department of Radiology.
Nele.Eley@sonopath.com