



PATIENT PRESENTING CLINICAL SIGNS

Buster Potts Narrow nostrils; History of several bouts of pneumonia; snores a lot

COMPUTED TOMOGRAPHIC STUDY OF THE HEAD

SPECIES Plain study available for review.

Canine **COMPUTED TOMOGRAPHIC FINDINGS**

The patient has a brachycephalic head conformation.

BREED Grade 3 stenosis of the nares is seen.

Boston Terrier The number and folding of the nasal turbinates are reduced. Mild retrograde elongation of the nasal turbinates is seen.

SEX The frontal sinuses are absent.

MN The nasopharyngeal lumen is narrow.

AGE The soft palate does not appear to be excessively long. Mild overlap between the palatine veil and tip of the epiglottis is seen, which is a normal finding, however thickening of the soft palate is noted. The maximum thickness of the soft palate is 11 mm.

3yr The tympanic bullae and external auditory meatuses are narrow. At this time there is no evidence of otitis.

INTERPRETED BY Supernumerous maxillary incisor teeth are noted.

Nele Eley (Ondreka), DVM Dr. med. vet., DipECVDI Generalized thickening of the laryngeal soft tissues is seen. The air is deviated mostly from the laryngeal ventricles.

COMPUTED TOMOGRAPHIC DIAGNOSIS

HOSPITAL NAME • Complex brachycephalic upper airway stenosis with stenotic nares, reduced number and folding of the turbinates, retrograde turbinate elongation, narrow nasopharyngeal lumen, thick soft palate and laryngeal edema.

State Avenue Vet Clinic

INTERPRETATION OF FINDINGS & FURTHER RECOMMENDATIONS

REFERRING VET The CT study reveals complex brachycephalic upper airway stenosis. The nares are stenotic. Shortening of the facial bone with reduced number and folding of the nasal turbinates and mild retrograde turbinate elongation is seen. The nasopharyngeal lumen is narrow. Nasopharyngeal collapse or thickening as well as pharyngitis should be considered.

Dr. Raul Casas

INVOICE Assessment of the soft palate is limited with CT. The soft palate appears to be thick and not necessarily excessively long. Differential diagnosis for the laryngeal thickening includes edema as well as laryngitis.

13624ag

DATE

04/27/2023



PATIENT

Buster Potts

SPECIES

Canine

BREED

Boston Terrier

SEX

MN

AGE

3yr

INTERPRETED BY

Nele Eley (Ondreka),
DVM Dr. med. vet.,
DipECVDI

HOSPITAL NAME

State Avenue Vet
Clinic

REFERRING VET

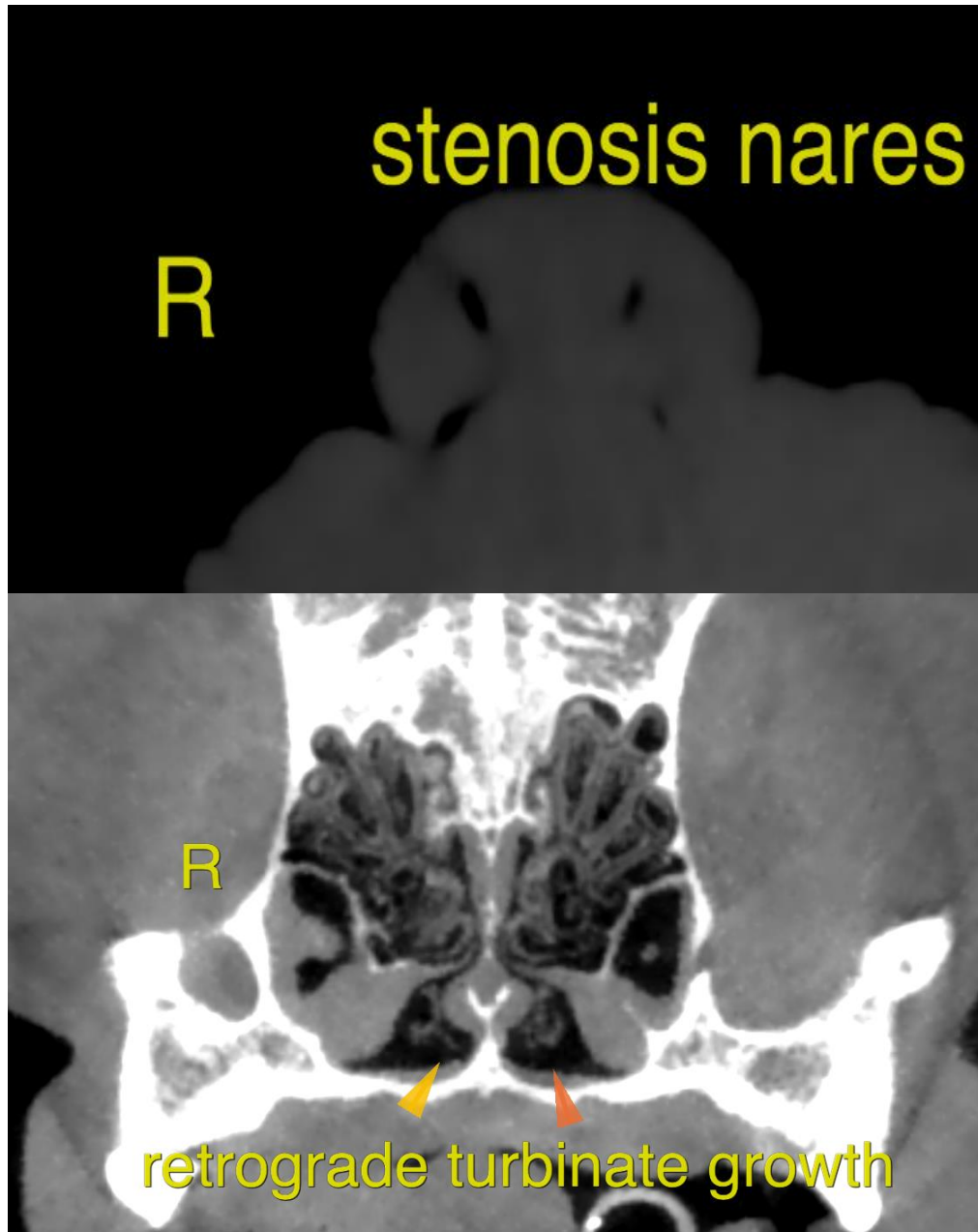
Dr. Raul Casas

INVOICE

13624ag

DATE

04/27/2023





PATIENT

Buster Potts

SPECIES

Canine

BREED

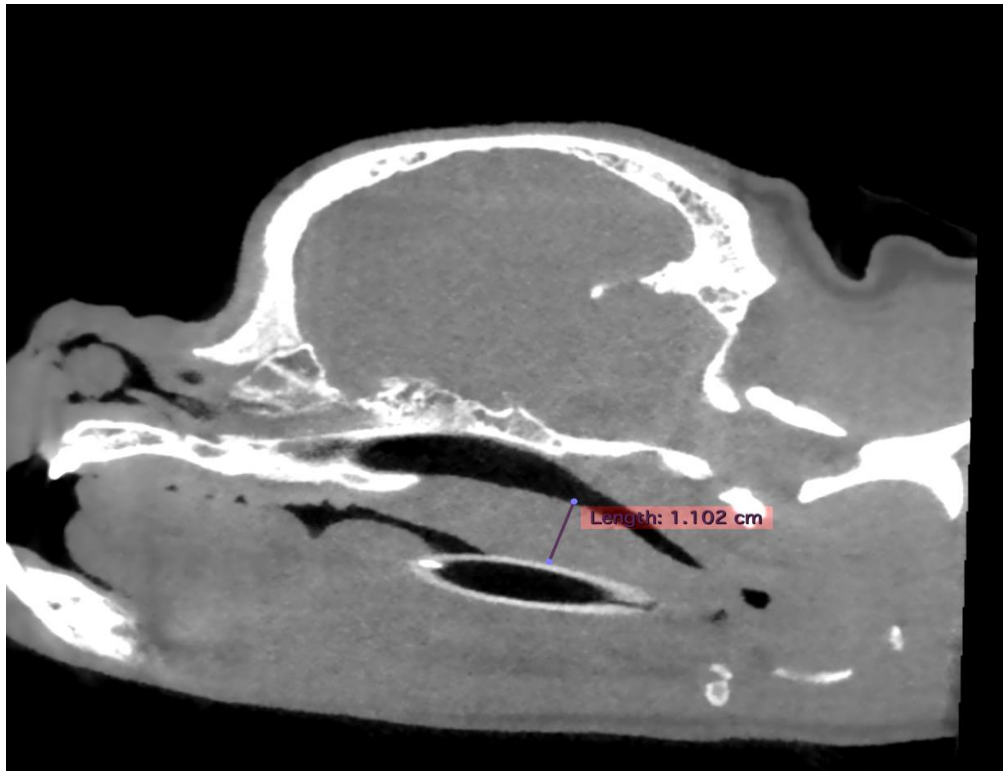
Boston Terrier

SEX

MN

AGE

3yr



INTERPRETED BY

Nele Eley (Ondreka),
DVM Dr. med. vet.,
DipECVDI

The information and recommendations provided are based on the images presented by the referring veterinarian. No evaluation can be communicated regarding pathology that was not visible in the image/video clips provided.

Thank you for this referral. If the clinical or image interpretation does not parallel your findings or if I can be of any further assistance please contact me.

HOSPITAL NAME

State Avenue Vet
Clinic

Nele Eley (Ondreka), DVM, Dr. med. vet., DipECVDI
European Specialist in Veterinary Diagnostic Imaging, Cert. Radiology,
Senior lecturer University of Giessen/Germany, Veterinary Faculty, Department of Radiology.
Nele.Eley@sonopath.com

REFERRING VET

Dr. Raul Casas

INVOICE

13624ag

DATE

04/27/2023



PATIENT

Buster Potts

SPECIES

Canine

BREED

Boston Terrier

SEX

MN

AGE

3yr

INTERPRETED BY

Nele Eley (Ondreka),
DVM Dr. med. vet.,
DipECVDI

HOSPITAL NAME

State Avenue Vet
Clinic

REFERRING VET

Dr. Raul Casas

INVOICE

13624ag

DATE

04/27/2023