



PATIENT

Tucker Walsh

SPECIES

K9

BREED

Great Pyrenees

SEX

MN

AGE

1 Year, 5 Months

INTERPRETED BY

Nele Eley, DVM
Dr. med. Vet. DipECVDI

HOSPITAL NAME

Blairstown Animal
Hospital

REFERRING VET

Dr. Lovell

INVOICE

51820

DATE

4-28-22

PRESENTING CLINICAL SIGNS

Submitted for review are 2 view rads of right hind tarsus. These are 1 month after previous rad consultation (3/10/22). Patient was placed on pred and doxy. Lameness resolved with therapy. Please compare current rads with those taken 3/10/22. Client considering FHO surgery but wants hock issue resolved prior to FHO's. Sedated palpation of hocks = WNL

RADIOGRAPHIC STUDY OF THE LEFT & RIGHT TARSUS

Mediolateral and dorsoplantar views of the left and right tarsus totaling 4 images available for review.

Findings compared to the prior report dated 3-10-22.

RADIOGRAPHIC FINDINGS

Mild residual articular swelling is seen level with the central distal tarsal joint accentuating its dorsal aspect. Residual subchondral bone erosion of the central and third tarsal bones is seen. The central distal and quartal joint spaces are collapsed and present incomplete fusion with the level of the joint space still being recognizable. The dorsal contour of the central distal joint, however, is bridged by smooth new bone formation and progressive sclerosis as well as fusion between the central distal and quartal bones is seen.

RADIOGRAPHIC DIAGNOSIS

- Progressive central distal and quartal ankylosis with chronic erosive arthropathy of the right tarsus.

INTERPRETATION OF THE FINDINGS & FURTHER RECOMMENDATIONS

Progressive fusion of the central distal and quartal joints is seen radiographically. Complete fusion and ankylosis is likely going to be the end result of the erosive arthropathy. At this time, no further progression or extension of the erosive changes to other joints is identified.



PATIENT

Tucker Walsh

SPECIES

K9

BREED

Great Pyrenees

SEX

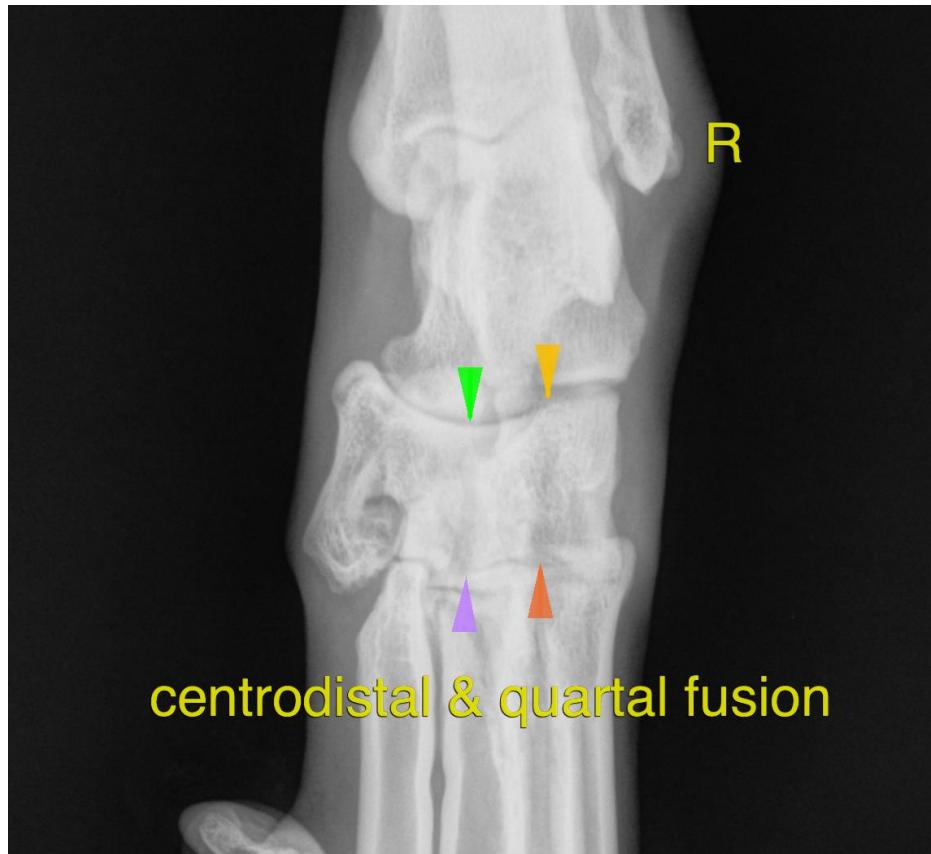
MN

AGE

1 Year, 5 Months

INTERPRETED BY

Nele Eley, DVM
Dr. med. Vet. DipECVDI



HOSPITAL NAME

Blairstown Animal
Hospital

REFERRING VET

Dr. Lovell

INVOICE

51820

DATE

4-28-22

The information and recommendations provided are based on the images presented by the referring veterinarian/sonographer. No evaluation can be communicated regarding pathology that was not visible in the image/video clips provided.

Thank you for this referral. If the clinical or image interpretation does not parallel your findings or if I can be of any further assistance please contact me.

Nele Eley, DVM, Dr. med. vet., DipECVDI
European Specialist in Veterinary Diagnostic Imaging, Cert. Radiology,
Senior lecturer University of Giessen, Germany, Veterinary Faculty, Department of Radiology
Nele.Eley@sonopath.com