

PATIENT

Pumpkin Priest

SPECIES

Canine

BREED

Labrador

SEX

FS

AGE

6

WEIGHT

27.1kg

INTERPRETED BY

Nele Eley (Ondreka),
DVM Dr. med. vet.,
DipECVDI

IMAGING PERFORMED BY

Hope

HOSPITAL NAME

CARE Surgery Center

REFERRING VET

Dr. Seth Bleakley

INVOICE

74782

DATE

4-27-26

PRESENTING CLINICAL SIGNS

Pt presented for perineal mass at primary veterinarian about 10 days ago, an aspirate was performed results suspected to be fatty. However, sample was severely contaminated with blood. Today's CT scan suggested lipoma. Mass was firmly attached to hamstring, ischium, and vulva.

COMPUTED TOMOGRAPHIC STUDY OF THE PELVIS

Plain and post contrast studies are available for review.

COMPUTED TOMOGRAPHIC FINDINGS

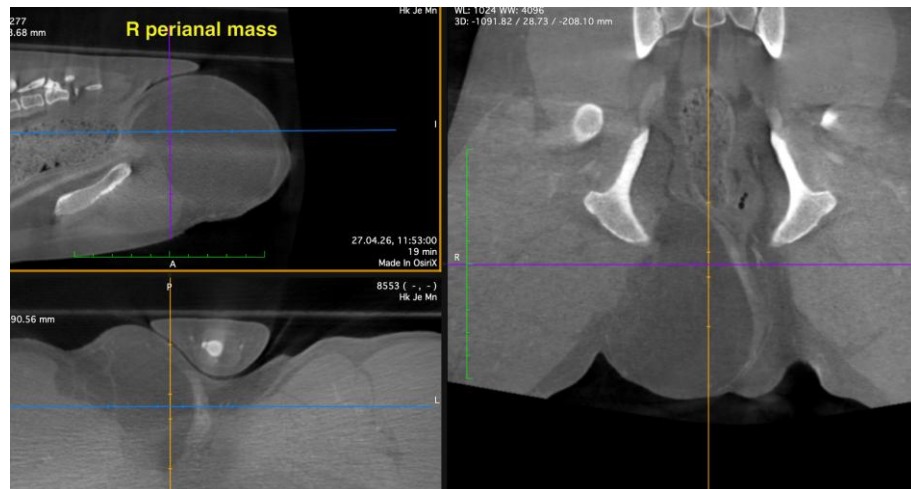
A well-defined, ovoid mass within the right perianal region measuring approximately 8 x 6 x 6 cm is seen. The mass is uniformly fat attenuating, well demarcated with smooth margins, and located between the sciatic bones closely associated with the right perineal musculature. Mild mass effect is present with slight leftward displacement of the rectum and mass effect on the anal sphincter and right anal sac. Mild lobulation is noted along the lateral aspect though margins of the individual lobules remain well defined without infiltration of peripheral tissues.

COMPUTED TOMOGRAPHIC DIAGNOSIS

- Well circumscribed fat attenuating mass in the right perianal region consistent with lipoma.
- Mild local mass effect.
- No CT evidence of malignancy.

INTERPRETATION OF FINDINGS & FURTHER RECOMMENDATIONS

The mass demonstrates imaging characteristics typical of benign lipoma including well defined margins and lack of invasive behavior. The mass, however, appears to be closely associated with the underlying right perineal muscles and is directly adjacent to the right sciatic bone, right wall of the rectum and anal sphincter, as well as the right anal sac. Surgical excision appears feasible based on the CT presentation. Histopathology is advised to confirm diagnosis and exclude rare other lipomatous variants.





PATIENT

Pumpkin Priest

SPECIES

Canine

BREED

Labrador

SEX

FS

AGE

6

WEIGHT

27.1kg

INTERPRETED BY

Nele Eley (Ondreka),
DVM Dr. med. vet.,
DipECVDI

IMAGING PERFORMED BY

Hope

HOSPITAL NAME

CARE Surgery Center

REFERRING VET

Dr. Seth Bleakley

INVOICE

74782

DATE

4-27-26

The information and recommendations provided are based on the images presented by the referring veterinarian. No evaluation can be communicated regarding pathology that was not visible in the image/video clips provided.

Thank you for this referral. If the clinical or image interpretation does not parallel your findings or if I can be of any further assistance please contact me.

Nele Eley (Ondreka), DVM, Dr. med. vet., DipECVDI

European Specialist in Veterinary Diagnostic Imaging, Cert. Radiology,
Senior lecturer University of Giessen/Germany, Veterinary Faculty, Department of Radiology.

info@sonopath.com