



PATIENT

Coby Bennett

PRESENTING CLINICAL SIGNS

p was referred here for an abdominal ultrasound by rdvm. p has had pancreatitis twice in past month. hx of laryngeal paralysis and neurological issues of hind end, has had surgery on a hip. has not eaten today

SPECIES

Canine

COMPUTED TOMOGRAPHIC STUDY OF THE ABDOMEN & THORAX

Plain study of the thorax and post contrast study of the abdomen available for review.

BREED

Border Collie Mix

COMPUTED TOMOGRAPHIC FINDINGS

Abdomen

Severe degenerative lumbosacral stenosis is noted.

SEX

Neutered Male

Severe spondyloses and multiple mild intervertebral disc protrusions are seen between T12, T13, L1, L2, L3, L4, L6, & L7.

The serosal fat presents normal attenuation behavior. There is no evidence of peritoneal effusion or peritonitis.

AGE

13

Occasional small cortical renal cysts are seen. The pyelogram presents within normal limits in both kidneys.

INTERPRETED BY

Nele Eley, DVM
Dr. med. Vet. DipECVDI

The adrenal glands are within normal limits for size, shape and organ architecture.

Occasional small hyperenhancing splenic nodules are noted.

The liver presents with normal shape, even surface, uniformly attenuating parenchyma and homogeneous contrast enhancement, unremarkable.

HOSPITAL NAME

Wilvet Salem

Motion related streak artifacts interfere with the assessment of the cranial abdomen. However, the pancreas presents mild generalized enlargement with no evidence of regional mesenteropathy.

REFERRING VET

Emi Menzen

Mild pancreaticoduodenal lymphadenomegaly is noted.

The position, delineation, wall and content of the gastrointestinal tract are considered within normal limits throughout.

INVOICE

58020

Thorax

Multiple thoracic spondyloses are seen.

There is a 4 x 3 cm sized lipoma within the left pectoralis muscle.

DATE

4-27-23

The sternal, cranial mediastinal and tracheobronchial lymph nodes are small elongated with a normal short-to-long-axis-ratio.

The cardiovascular structures including the pulmonary vasculature are within normal limits.



PATIENT

Coby Bennett

Multiple pulmonary osteomas are seen. There is no evidence of interstitial pulmonary nodules or masses.

SPECIES

Canine

Small incidental gas pockets are seen within the esophageal lumen, there is no evidence of abnormal dilation.

BREED

Border Collie Mix

COMPUTED TOMOGRAPHIC DIAGNOSIS

- Pancreatopathy
- Mild pancreaticoduodenal lymphadenomegaly.
- Small cortical renal cysts
- Splenic nodules
- Multiple chronic degenerative disc disease and spondyloses.
- Multiple mild intervertebral disc protrusions.
- Severe degenerative lumbosacral stenosis.
- Normal age related lung.

SEX

Neutered Male

AGE

13

INTERPRETATION OF THE FINDINGS & FURTHER RECOMMENDATIONS

The CT findings are compatible with pancreatopathy. Chronic pancreatitis is a primary differential diagnosis. Benign age related nodular hyperplasia cannot be ruled out entirely as a differential diagnosis.

INTERPRETED BY

Nele Eley, DVM
Dr. med. Vet. DipECVDI

The mild regional lymphadenomegaly is compatible with reactive lymphadenitis.

The splenic nodules are likely to represent lymphoid hyperplasia or extramedullary hematopoiesis. Neoplasia is thought unlikely but can never be ruled out entirely.

The renal cysts are likely to be degenerative in origin. Chronic nephritis cannot be ruled out.

HOSPITAL NAME

Wilvet Salem

REFERRING VET

Emi Menzen

INVOICE

58020

DATE

4-27-23



PATIENT

Coby Bennett

SPECIES

Canine

BREED

Border Collie Mix

SEX

Neutered Male

AGE

13

INTERPRETED BY

Nele Eley, DVM
Dr. med. Vet. DipECVDI

HOSPITAL NAME

Wilvet Salem

REFERRING VET

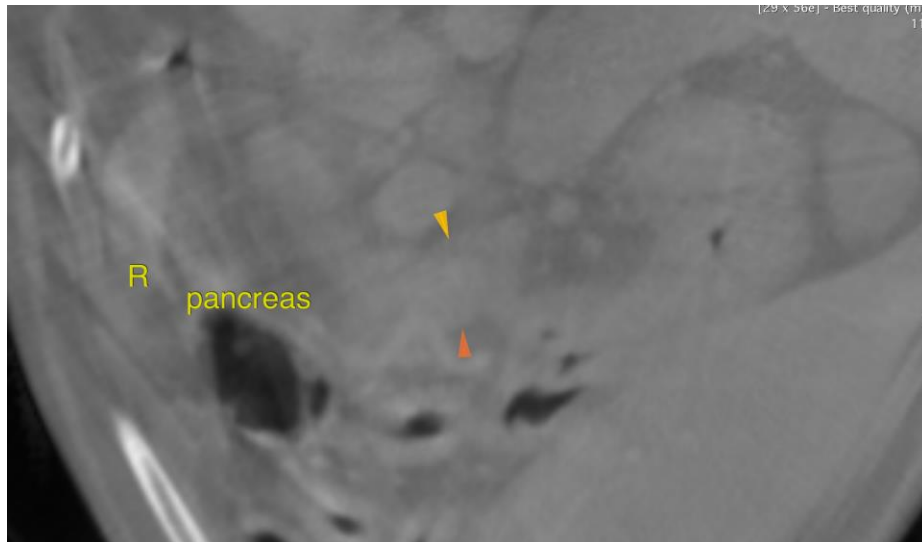
Emi Menzen

INVOICE

58020

DATE

4-27-23



The information and recommendations provided are based on the images presented by the referring veterinarian/sonographer. No evaluation can be communicated regarding pathology that was not visible in the image/video clips provided.

Thank you for this referral. If the clinical or image interpretation does not parallel your findings or if I can be of any further assistance please contact me.

Nele Eley, DVM, Dr. med. vet., DipECVDI
European Specialist in Veterinary Diagnostic Imaging, Cert. Radiology,
Senior lecturer University of Giessen, Germany, Veterinary Faculty, Department of Radiology
Nele.Eley@sonopath.com