



PATIENT

Ukkonen Burbeck

PRESENTING CLINICAL SIGNS

Nasal discharge since 9 weeks of age. Sometimes the discharge is bloody and sneezes violently. No treatment has changed the discharge significantly. Sometimes collapses after play and has difficulty breathing. Has Feline leukemia positive housemates. Clavamox and Flamcyclovir have both been prescribed with no improvement.

SPECIES

Feline

Abnormal PE/Chem/CBC/UA Results: Nasal discharge (mostly thick and clear with slight amount of blood) from left nostril. Crusts under left nostril. Tested positive for Feline leukemia in Feb. 2022. Normal Chem & CBC today

BREED

Ragdoll

COMPUTED TOMOGRAPHIC STUDY OF THE HEAD

Plain and post contrast studies available for review.

SEX

MN

COMPUTED TOMOGRAPHIC FINDINGS

Moderate turbinate destruction is noted within the rostral and mid third of both nasal cavities. Extensive accumulation of fluid secretions are seen within the left nasal cavity. Multifocal moderate swelling of the mucosal lining of the turbinates and nasal cavum is seen bilaterally. The left frontal sinus contains a mild amount of fluid attenuating material. Moderate swelling of the mucosal lining of the left frontal sinus is seen. A moderate amount of fluid attenuating material is present within the presphenoidal sinus and nasal fundus. Mild hyperostosis of the frontal bones and nasal bones is seen.

AGE

6 Months

There is moderate bilaterally symmetric submandibular and medial retropharyngeal lymphadenomegaly.

INTERPRETED BY

Nele Eley, DVM
Dr. med. Vet. DipECVDI

COMPUTED TOMOGRAPHIC DIAGNOSIS

- Chronic bilateral destructive rhinosinusitis.
- Moderate bilateral retropharyngeal and submandibular lymphadenomegaly.

HOSPITAL NAME

Casselton Vet Service

INTERPRETATION OF THE FINDINGS & FURTHER RECOMMENDATIONS

The CT study reveals chronic bilateral destructive rhinosinusitis. Differential diagnosis includes chronic viral or bacterial rhinitis and less likely fungal infection or lymphoplasmacytic rhinitis. There is no evidence of a soft tissue mass, relevant dental changes, or foreign material. Further definition by means of upper airway sampling is recommended.

REFERRING VET

Laurie Huckle

The lymph node changes are compatible with reactive lymphadenitis.

INVOICE

51788

DATE

4-27-22



PATIENT

Ukkonen Burbeck

SPECIES

Feline

BREED

Ragdoll

SEX

MN

AGE

6 Months

INTERPRETED BY

Nele Eley, DVM
Dr. med. Vet. DipECVDI

HOSPITAL NAME

Casselton Vet Service

REFERRING VET

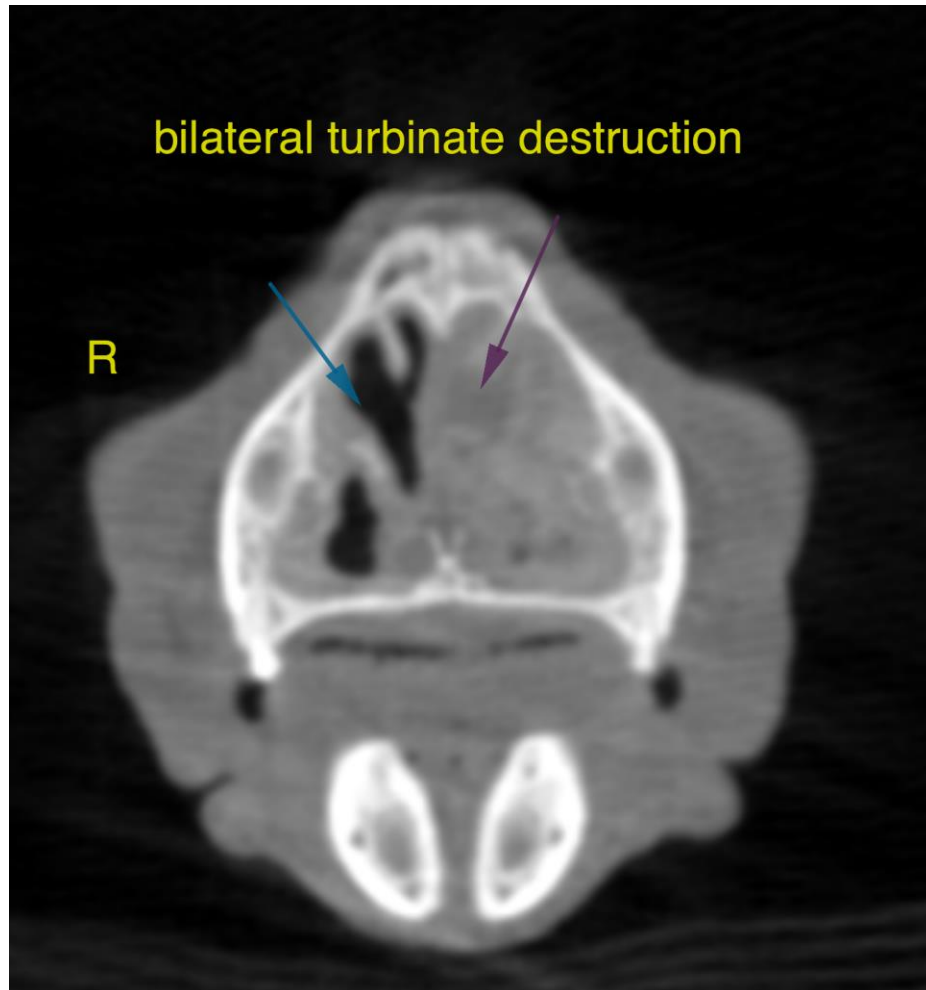
Laurie Huckle

INVOICE

51788

DATE

4-27-22



The information and recommendations provided are based on the images presented by the referring veterinarian/sonographer. No evaluation can be communicated regarding pathology that was not visible in the image/video clips provided.

Thank you for this referral. If the clinical or image interpretation does not parallel your findings or if I can be of any further assistance please contact me.

Nele Eley, DVM, Dr. med. vet., DipECVDI
European Specialist in Veterinary Diagnostic Imaging, Cert. Radiology,
Senior lecturer University of Giessen, Germany, Veterinary Faculty, Department of Radiology
Nele.Eley@sonopath.com