



**PATIENT PRESENTING CLINICAL SIGNS**

Tribi Rivera E/U/D OK Drinking excessive water Was coughing before - better now Vomits in the middle of the night

**SPECIES RADIOGRAPHIC STUDY OF THE ABDOMEN & THORAX**

Canine Right lateral and ventrodorsal views of the abdomen and right/left lateral and ventrodorsal views of the thorax totaling 5 images available for review.

**BREED RADIOGRAPHIC FINDINGS**

Jack Russell Terrier **Abdomen**

The abdominal cavity is voluminous.

**SEX** The ventral abdominal wall is pendulous.

Male The urinary bladder presents within normal limits.

**AGE** The prostate appears to be moderately enlarged which is within the expected limits in a non-neutered male.

15 Moderate enlargement of the liver with slightly irregular margins is noted. There is caudodorsal deviation of the gastric pylorus.

**INTERPRETED BY** The stomach is post-prandial.

Nele Eley, DVM  
Dr. med. Vet. DipECVDI The small intestinal loops are evenly distributed throughout the mid abdomen.

**HOSPITAL NAME** The colon contains a moderate amount of fecal matter.

Animal Paradise Hospital Moderate generalized osteopenia is seen.

There is mild spondylosis deformans within the lumbar spine between L1/2 and L2/3.

**REFERRING VET Thorax**

Dr. Elshafie There is bilateral elbow osteoarthritis.

An ovoid soft tissue opaque mass of approximately 3.0 cm diameter is seen within the dorsal and cranial aspect of the left caudal lung lobe. No other pulmonary nodules or masses are seen.

**INVOICE** The radiographic presentation of the cardiac silhouette is within normal limits.

51793 Course and width of the trachea are within normal limits.

**DATE**

4-27-22



**PATIENT**

Tribi Rivera

**RADIOGRAPHIC DIAGNOSIS**

- Hepatomegaly with mass effect.
- Single pulmonary mass within the left caudal lung lobe.

**SPECIES**

Canine

**INTERPRETATION OF THE FINDINGS & FURTHER RECOMMENDATIONS**

Differential diagnosis for the pulmonary mass includes primary and secondary pulmonary neoplasia such as bronchial carcinoma, pulmonary sarcoma, round cell neoplasia, or metastatic disease.

**BREED**

Jack Russell Terrier

There is evidence of hepatomegaly with irregular enlargement of the liver accentuating its right division. Liver mass such as neoplasia, nodular hyperplasia, and other hepatopathy are potential considerations. Further definition would require ultrasound or CT.

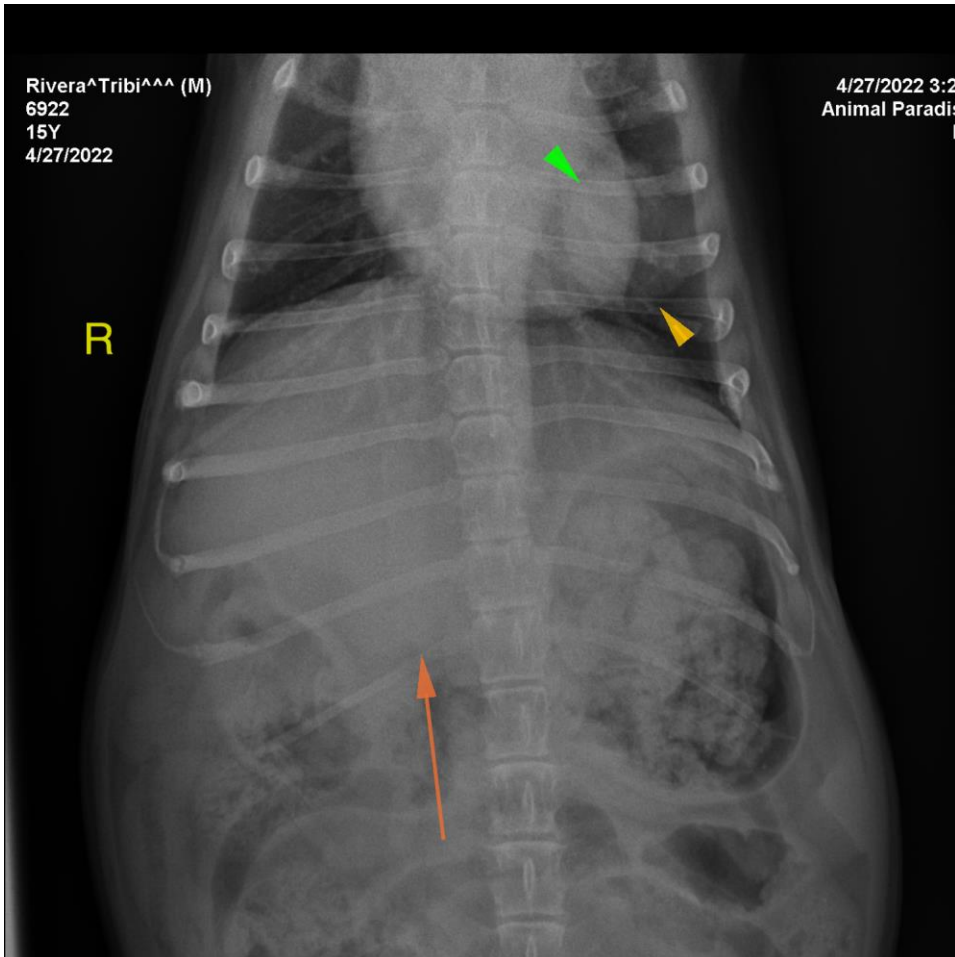
**SEX**

Male

CT of the thorax and abdomen could be considered if the owner is interested in pursuing staging and surgery.

**AGE**

15



**INTERPRETED BY**

Nele Eley, DVM  
Dr. med. Vet. DipECVDI

**HOSPITAL NAME**

Animal Paradise  
Hospital

**REFERRING VET**

Dr. Elshafie

**INVOICE**

51793

**DATE**

4-27-22



**PATIENT**

Tribi Rivera

The information and recommendations provided are based on the images presented by the referring veterinarian/sonographer. No evaluation can be communicated regarding pathology that was not visible in the image/video clips provided.

**SPECIES**

Canine

Thank you for this referral. If the clinical or image interpretation does not parallel your findings or if I can be of any further assistance please contact me.

**BREED**

Jack Russell Terrier

**Nele Eley**, DVM, Dr. med. vet., DipECVDI  
European Specialist in Veterinary Diagnostic Imaging, Cert. Radiology,  
Senior lecturer University of Giessen, Germany, Veterinary Faculty, Department of Radiology  
Nele.Eley@sonopath.com

**SEX**

Male

**AGE**

15

**INTERPRETED BY**

Nele Eley, DVM  
Dr. med. Vet. DipECVDI

**HOSPITAL NAME**

Animal Paradise  
Hospital

**REFERRING VET**

Dr. Elshafie

**INVOICE**

51793

**DATE**

4-27-22