



**PATIENT PRESENTING CLINICAL SIGNS**

Tiny Santos Presented 4/20 to check ear. Owner reported pet can't hear for the past few days. No response to noise, doorbell. Ear canal exam WNL's. Presented 3/31 for a broken tooth, had dental with extraction. Concern for liver disease, rule out liver shunt. Previous Hx of exercise intolerance.

**SPECIES COMPUTED TOMOGRAPHIC STUDY OF THE HEAD, THORAX, & ABDOMEN**

Canine Plain and post contrast studies of the abdomen and head in open and closed mouth positions, and post contrast study only of the thorax available for review.

**BREED COMPUTED TOMOGRAPHIC FINDINGS**

Maltese **Head**

**SEX** The patient is a brachycephalic dog and has a history of prior dental extractions.

Spayed Female Ventral deviation and lateral incline of the right mandible is seen. The mandibular symphysis however is intact, and the temporomandibular joints are in situ. The condylar processes of both mandibles appear to be small however there is no evidence of luxation or subluxation in the closed and open mouthed positions.

**AGE** 3 Years The brain presents no deviation from normal anatomy and symmetry. The grey and white matter distinction and the neuroparenchymal attenuation are as expected. The distribution of contrast enhancement is within normal limits throughout the parenchyma and meninges. The ventricular system is non-dilated and within the limits of the expected volume and symmetry.

**INTERPRETED BY**

Nele Eley (Ondreka),  
DVM Dr. med. vet.,  
DipECVDI

Both tympanic bullae are aerated, the mucosal lining is not seen, the bony wall is smooth and thin. The external auditory meatuses present within normal limits.

The submandibular and medial retropharyngeal lymph nodes are small and elongated with a normal short-to-long-axis-ratio is < 0.5, the attenuation and contrast enhancement pattern is uniform.

**HOSPITAL NAME Thorax**

Mobile Pet Imaging The bony and surrounding soft tissue structures are within normal limits.

**REFERRING VET**

Meaux

The sternal, cranial mediastinal and tracheobronchial lymph nodes are small elongated with a normal short-to-long-axis-ratio is < 0.5, the attenuation and contrast enhancement pattern are uniform and considered within normal limits.

The cardiovascular structures including the pulmonary vasculature are within normal limits.

**INVOICE**

51787

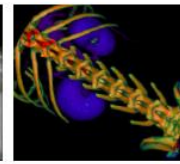
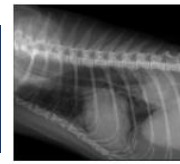
The bronchial tree presents with regular branching and tapers uniformly towards the periphery as expected, the bronchial walls are thin and smooth. The bronchus-to-artery ratio is within normal limits.

The lung parenchyma presents the expected architecture and attenuation behavior.

**DATE**

4-27-22

Small incidental gas pockets are seen within the esophageal lumen, there is no evidence of abnormal dilation.



**PATIENT**

**Abdomen**

Tiny Santos

The serosal fat presents normal attenuation behavior. There is no evidence of peritoneal effusion or peritonitis.

**SPECIES**

Canine

Both kidneys present within normal limits for size, shape and organ architecture. After contrast administration a bilaterally symmetric and uniform nephro- and pyelogram is noted.

The adrenal glands are within normal limits for size, shape and organ architecture.

**BREED**

Maltese

Both liver and spleen present with normal shape, even surface, uniformly attenuating parenchyma and homogeneous contrast enhancement, unremarkable.

The portal vein presents a normal order of its tributary veins and intrahepatic branching. No abnormal vessel is noted inside and outside of the liver parenchyma.

**SEX**

Spayed Female

The pancreas is evenly contoured, the pancreatic parenchyma is homogeneous and presents uniform contrast enhancement.

**AGE**

3 Years

The position, delineation, wall and content of the gastrointestinal tract are considered within normal limits throughout.

The bony and surrounding soft tissue structures reveal no abnormalities.

**INTERPRETED BY**

Nele Eley (Ondreka),  
DVM Dr. med. vet.,  
DipECVDI

**COMPUTED TOMOGRAPHIC DIAGNOSIS**

- Mandibular asymmetry
- Suspect underdevelopment of both mandibular condyles.
- Structurally normal CT study of the brain.
- Structurally normal CT findings of the middle ear and external auditory meatuses.
- No evidence of portosystemic shunt.
- Normal CT findings of the cardiovascular system.

**HOSPITAL NAME**

Mobile Pet Imaging

**INTERPRETATION OF FINDINGS & FURTHER RECOMMENDATIONS**

The CT study reveals mandibular asymmetry with ventrolateral incline of the right mandible. No evidence of mandibular symphysiolysis or temporomandibular joint luxation is seen. However, the mandibles and especially the condylar processes of both mandibles appear to be small and increased laxity/dynamic subluxation of the temporomandibular joints cannot be ruled out entirely. A developmental malformation is thought more likely than prior traumatic injury as underlying cause of the jaw asymmetry.

**REFERRING VET**

Meaux

**INVOICE**

51787

There is no evidence of a portosystemic shunt. Liver biopsies could be considered for further definition should there be strong evidence of hepatic dysfunction.

The brain, inner and middle ear, and the external auditory meatuses all present within normal limits.

**DATE**

4-27-22



**PATIENT**

Tiny Santos

**SPECIES**

Canine

**BREED**

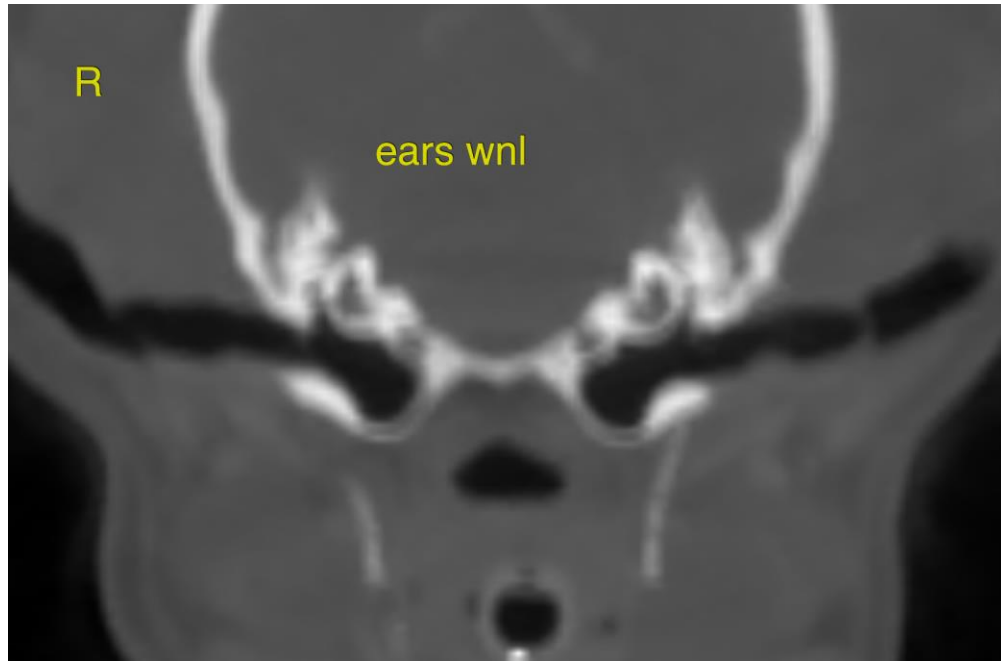
Maltese

**SEX**

Spayed Female

**AGE**

3 Years



**INTERPRETED BY**

Nele Eley (Ondreka),  
DVM Dr. med. vet.,  
DipECVDI

The information and recommendations provided are based on the images presented by the referring veterinarian. No evaluation can be communicated regarding pathology that was not visible in the image/video clips provided.

Thank you for this referral. If the clinical or image interpretation does not parallel your findings or if I can be of any further assistance please contact me.

**HOSPITAL NAME**

Mobile Pet Imaging

**Nele Eley (Ondreka)**, DVM, Dr. med. vet., DipECVDI  
European Specialist in Veterinary Diagnostic Imaging, Cert. Radiology,  
Senior lecturer University of Giessen/Germany, Veterinary Faculty, Department of Radiology.  
Nele.Eley@sonopath.com

**REFERRING VET**

Meaux

**INVOICE**

51787

**DATE**

4-27-22