



PATIENT

Ruger Tescher

PRESENTING CLINICAL SIGNS

History of pneumonia in November. owner feels pet is congested and lethargic

SPECIES

Canine

RADIOGRAPHIC STUDY OF THE THORAX

Right/left lateral and ventrodorsal views of the thorax totaling 3 images available for review.

BREED

Great Dane

RADIOGRAPHIC FINDINGS

The degree of pulmonary inflation is moderate. A moderate generalized bronchointerstitial lung pattern is seen and evenly distributed throughout the lung. Moderate peribronchial cuffing is noted. Plate-like atelectasis is present between the left caudal and left cranial lung lobes which is an incidental finding and can be appreciated on the orthogonal view.

SEX

Male Neutered

There is no evidence of mediastinal lymphadenomegaly.

Course and width of the trachea are considered within normal limits.

The radiographic presentation of the cardiac silhouette is considered within normal limits.

AGE

7

RADIOGRAPHIC DIAGNOSIS

- Moderate generalized bronchointerstitial lung pattern.

INTERPRETED BY

Nele Eley, DVM
Dr. med. Vet. DipECVDI

INTERPRETATION OF THE FINDINGS & FURTHER RECOMMENDATIONS

The radiographic findings are suggestive for presence of lower airway disease. Infectious bronchitis such as viral, bacterial, and less likely parasitic, or protozoal should be considered as well as eosinophilic bronchopneumopathy. Further definition by means of lower airway endoscopy with airway sampling would be ideal.

HOSPITAL NAME

Pacific Avenue
Veterinary Clinic

REFERRING VET

Sid Bruckert-Frisk

INVOICE

51800

DATE

4-27-22



PATIENT

Ruger Tescher

SPECIES

Canine

BREED

Great Dane

SEX

Male Neutered

AGE

7

INTERPRETED BY

Nele Eley, DVM
Dr. med. Vet. DipECVDI

HOSPITAL NAME

Pacific Avenue
Veterinary Clinic

REFERRING VET

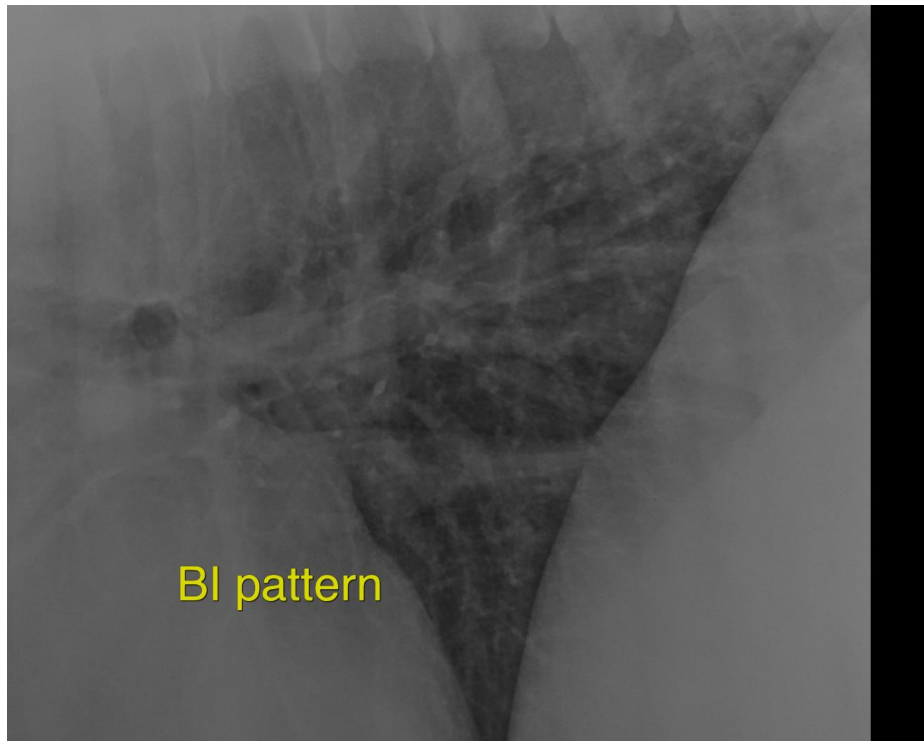
Sid Bruckert-Frisk

INVOICE

51800

DATE

4-27-22



The information and recommendations provided are based on the images presented by the referring veterinarian/sonographer. No evaluation can be communicated regarding pathology that was not visible in the image/video clips provided.

Thank you for this referral. If the clinical or image interpretation does not parallel your findings or if I can be of any further assistance please contact me.

Nele Eley, DVM, Dr. med. vet., DipECVDI
European Specialist in Veterinary Diagnostic Imaging, Cert. Radiology,
Senior lecturer University of Giessen, Germany, Veterinary Faculty, Department of Radiology
Nele.Eley@sonopath.com