



PATIENT PRESENTING CLINICAL SIGNS

PATIENT
Missy Hodge

SPECIES
Canine

BREED
Mastiff

SEX
Female

P presents for rads of bladder, urine culture, and vaginal cytology. P is currently in heat. P is to be sedated for rads due to aggression. Per O P has had a UTI of and on for the past year. When gets a UTI...pollakiuria, licking vulva excessively, no stranguria Currently asymptomatic
 Abnormal PE/Chem/CBC/UA Results: Doctor Notes: SEDATED, Vulva enlarged/in heat but there is a small amt of pink purulent vaginal discharge and mild dermatitis in dorsal vulvar fold.
 Ab Palp WNL X-rays - uterus not obviously enlarged, no stones in bladder or kidneys seen quick scan US - no masses or stones seen in urinary bladder/prox urethra Vaginal exam - normal other than pair of 1-2 mm firm bumps on floor of vagina, mildly recessed vulva, and pink purulent vaginal discharge Cytology of vaginal discharge - TNTC Rods Client Communication: SW MR, looks like all prior UA's have been free catch that we have been diagnosing her with UTI's. The last culture doesn't specify if free catch or cysto. The cysto sample today looked very clear but will see what culture shows. I suspect if urine culture neg then she is suffering from chronic vaginitis in part to recessed vulva. He has not been cleaning daily with Malacetic wipes as recommended, I would try to do at least 2x/day lifelong. I would also rec OVH and correcting recessed vulva....would need to be done with boarded surgeon. She is certainly going to be at higher risk of a pyometra...another good reason to spay her.

RADIOGRAPHIC FINDINGS

AGE Abdomen

2 Years, 2 Months
The abdominal cavity is voluminous.

INTERPRETED BY
The abdominal serosal detail is maintained.

Nele Eley, DVM
Dr. med. Vet. DipECVDI
The urinary bladder is mildly distended and seen within the caudoventral abdomen. No evidence of abnormal opacities is seen within the urinary bladder even though the descending colon with fecal matter is superimposed onto the urinary bladder.

HOSPITAL NAME
At least one of the uterine horns is seen superimposed onto the ventral aspect of the urinary bladder.

DPC Veterinary Hospital
The splenic tail presents within the expected limits.

REFERRING VET
The stomach is post-prandial.

Dr. Feldt
The assessment of the kidneys is limited owing to superimposition with the gastrointestinal tract.

The mamils appear to be enlarged.

INVOICE RADIOGRAPHIC DIAGNOSIS

- 51781
- Uterine enlargement.
 - Normal radiographic presentation of the urinary bladder.

DATE

4-27-22



PATIENT

Missy Hodge

INTERPRETATION OF THE FINDINGS & FURTHER RECOMMENDATIONS

The uterine enlargement may be an uncomplicated consequence of the hormonal state since the patient is in heat at this point. However, uterine wall thickening and/or fluid content of the uterus such as mucometra, pyometra, hemometra, or other cannot be ruled out.

SPECIES

Canine

Abdominal ultrasound could be discussed for further definition of the presumed lower urinary tract disease and to further define the character and degree of the uterine enlargement. However, full urinalysis and ovariohysterectomy are potential points of discussion in this patient as well.

BREED

Mastiff

SEX

Female

AGE

2 Years, 2 Months

INTERPRETED BY

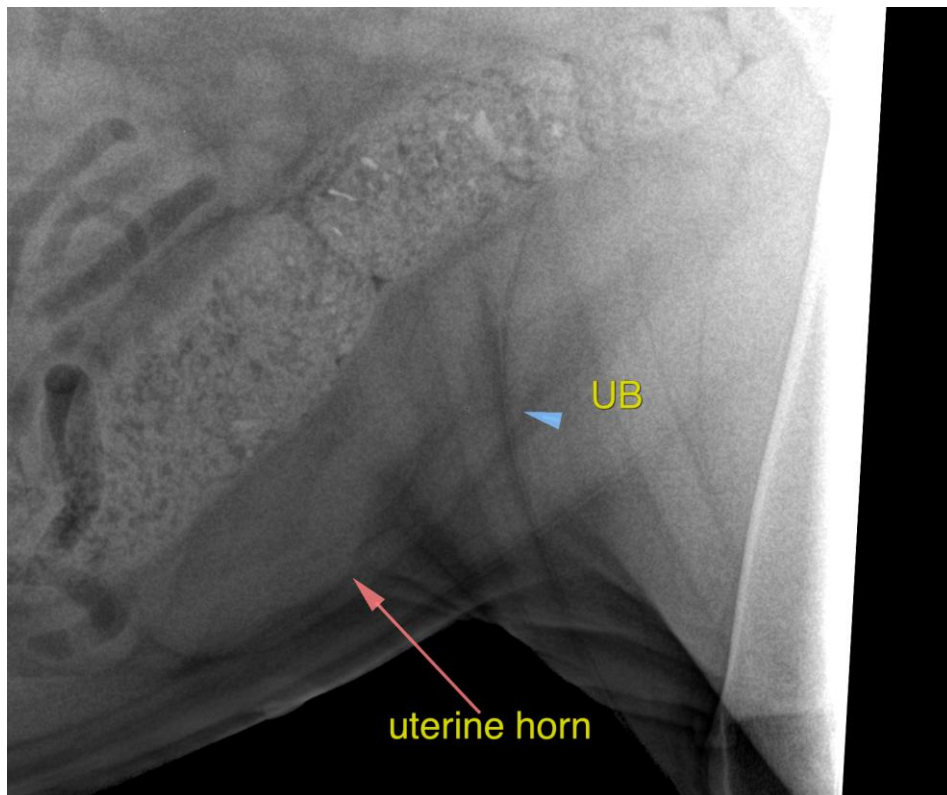
Nele Eley, DVM
Dr. med. Vet. DipECVDI

HOSPITAL NAME

DPC Veterinary
Hospital

REFERRING VET

Dr. Feldt



INVOICE

51781

The information and recommendations provided are based on the images presented by the referring veterinarian/sonographer. No evaluation can be communicated regarding pathology that was not visible in the image/video clips provided.

Thank you for this referral. If the clinical or image interpretation does not parallel your findings or if I can be of any further assistance please contact me.

DATE

4-27-22

Nele Eley, DVM, Dr. med. vet., DipECVDI
European Specialist in Veterinary Diagnostic Imaging, Cert. Radiology,
Senior lecturer University of Giessen, Germany, Veterinary Faculty, Department of Radiology
Nele.Eley@sonopath.com