



PATIENT

Chou Chou Garcia

PRESENTING CLINICAL SIGNS

P has a dry cough and vomiting yellow foam also P has diarrhea with blood and mucus ok e/d/u

SPECIES

Canine

RADIOGRAPHIC STUDY OF THE THORAX & ABDOMEN

Right/left lateral and ventrodorsal views of the thorax and abdomen totaling 6 images available for review.

BREED

Shih Tzu

RADIOGRAPHIC FINDINGS

Thorax

A mild generalized bronchointerstitial lung pattern is noted and evenly distributed throughout the lung.

SEX

Male

The radiographic presentation of the cardiac silhouette is within normal limits.

There is mild redundancy of the dorsal tracheal ligament of the cervical trachea which is an incidental finding. No true collapse of the trachea is seen.

AGE

1

There is no evidence of abnormal mediastinal widening.

Abdomen

The abdominal serosal detail is maintained.

The gastrointestinal tract is mostly empty. A mild amount of gas is seen within the stomach.

The small intestinal loops are evenly distributed throughout the abdomen. No evidence of abnormal dilation, plication, or radiopaque foreign material is seen.

The descending colon contains a moderate amount of gas.

The liver, spleen, kidneys, and urinary bladder present within normal radiographic limits.

RADIOGRAPHIC DIAGNOSIS

- Mild generalized bronchointerstitial lung pattern.
- Empty gastrointestinal tract without evidence of mechanical ileus.

INTERPRETATION OF THE FINDINGS & FURTHER RECOMMENDATIONS

The mild bronchointerstitial lung pattern may be an incidental finding; however, low grade lower airway disease such as infectious bronchitis including viral, bacterial, parasitic, eosinophilic bronchopneumopathy, or irritant bronchitis cannot be ruled out. Further definition by means of lower airway endoscopy with airway sampling could be considered.

At this time, there is no radiographic evidence of mechanical ileus. Abdominal ultrasound could be considered for further definition should the patient's clinical signs persist.

INTERPRETED BY

Nele Eley, DVM
Dr. med. Vet. DipECVDI

HOSPITAL NAME

Animal Paradise
Hospital

REFERRING VET

Dr. Elshafie

INVOICE

51801

DATE

4-27-22



PATIENT

Chou Chou Garcia

SPECIES

Canine

BREED

Shih Tzu

SEX

Male

AGE

1

INTERPRETED BY

Nele Eley, DVM
Dr. med. Vet. DipECVDI

HOSPITAL NAME

Animal Paradise
Hospital

REFERRING VET

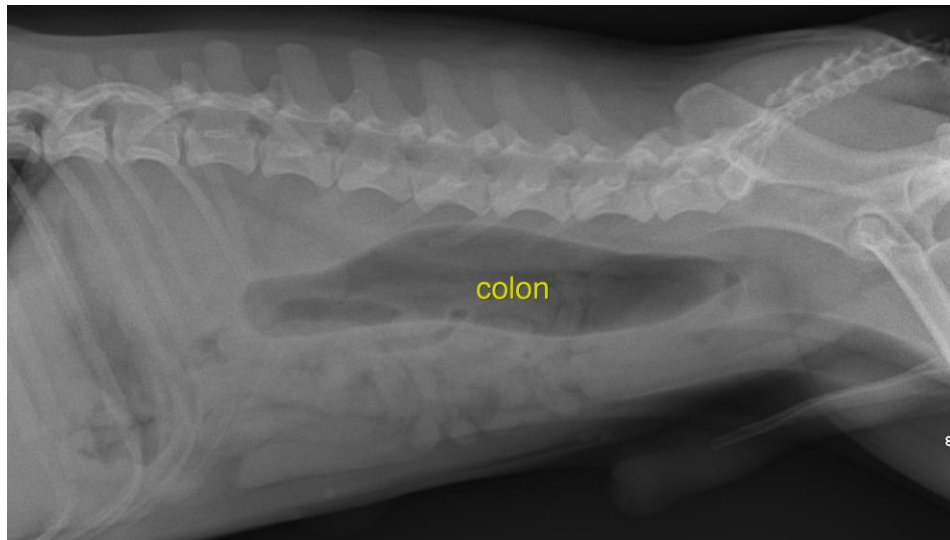
Dr. Elshafie

INVOICE

51801

DATE

4-27-22



The information and recommendations provided are based on the images presented by the referring veterinarian/sonographer. No evaluation can be communicated regarding pathology that was not visible in the image/video clips provided.

Thank you for this referral. If the clinical or image interpretation does not parallel your findings or if I can be of any further assistance please contact me.

Nele Eley, DVM, Dr. med. vet., DipECVDI
European Specialist in Veterinary Diagnostic Imaging, Cert. Radiology,
Senior lecturer University of Giessen, Germany, Veterinary Faculty, Department of Radiology
Nele.Eley@sonopath.com